

Pre-Lab

Name: _____

8. Blood Vessels

- The walls of the large blood vessels are composed of three layers:
_____, _____, and _____
- Arteries carry blood from the _____ to the _____. All arteries carry oxygenated blood except the _____ trunk and its branches.
- Veins return blood from the _____ to the _____. All veins carry deoxygenated blood except the _____ veins.
- What is the function of capillaries? _____
- Which types of capillaries would you find in each of these organs?
Liver: _____
Skeletal muscle: _____
Choroid plexus: _____
Kidney: _____
- When blood makes a circuit through a portal system, it travels through _____ capillary beds.
- Define the following:
A. Blood pressure: _____

B. Pulse: _____

- How are the heart rate and pulse rate related?

- The three branches that come off from the arch of aorta are:

- The three veins that return blood into the right atrium are _____,
_____ and _____.



Name: _____

Date: _____

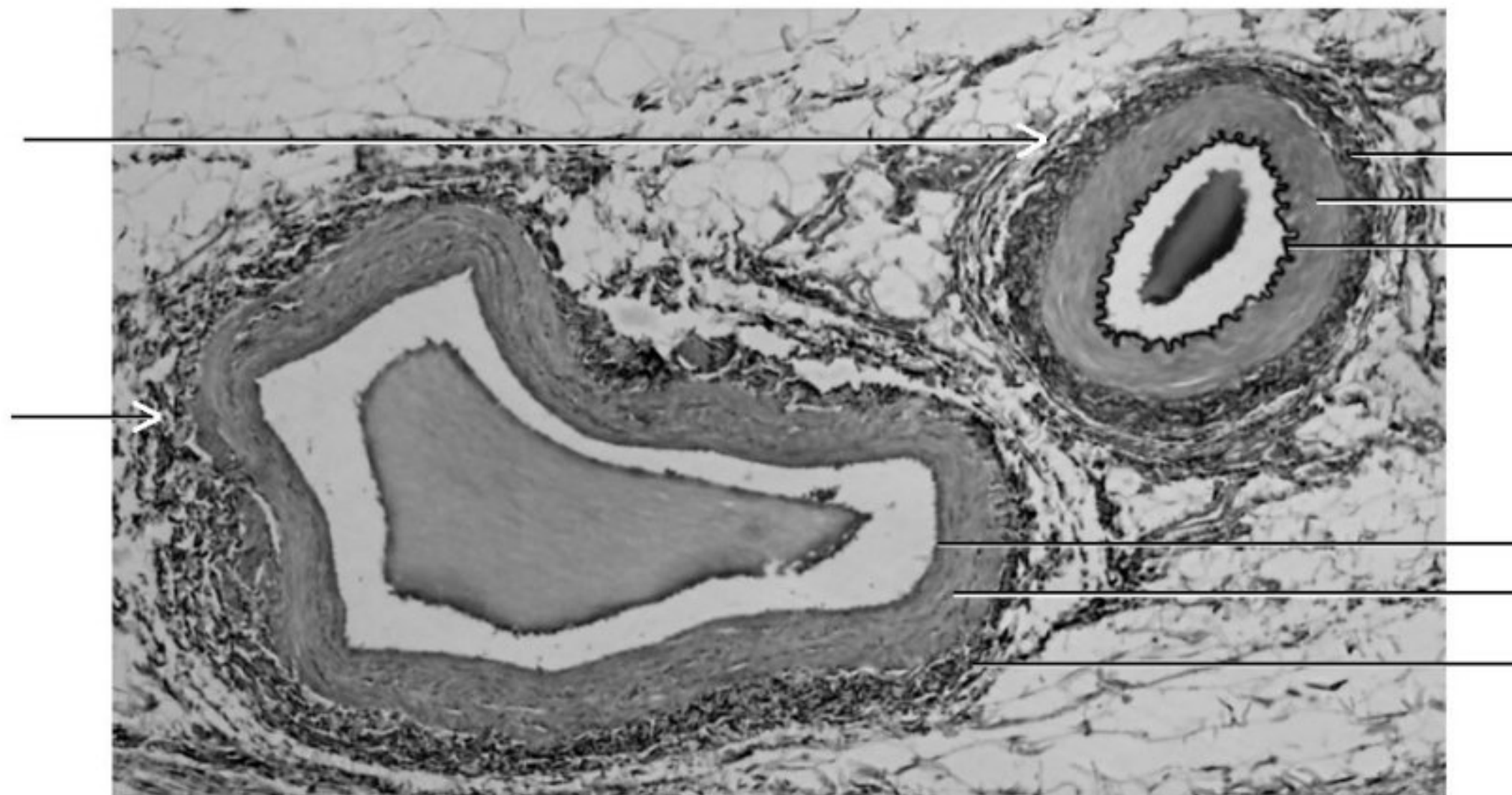
8. Blood Vessels

A. Histology of blood vessels

- Label the arrows on the left side of the image with the types of blood vessels: **artery**, **vein**
Then label on the right side of the image with the specific layers of their wall: **tunica externa**, **tunica interna**, **tunica media**

Label artery/vein

Label specific layers



- Complete the following table contrasting the structure of arteries and veins that are equal in size.

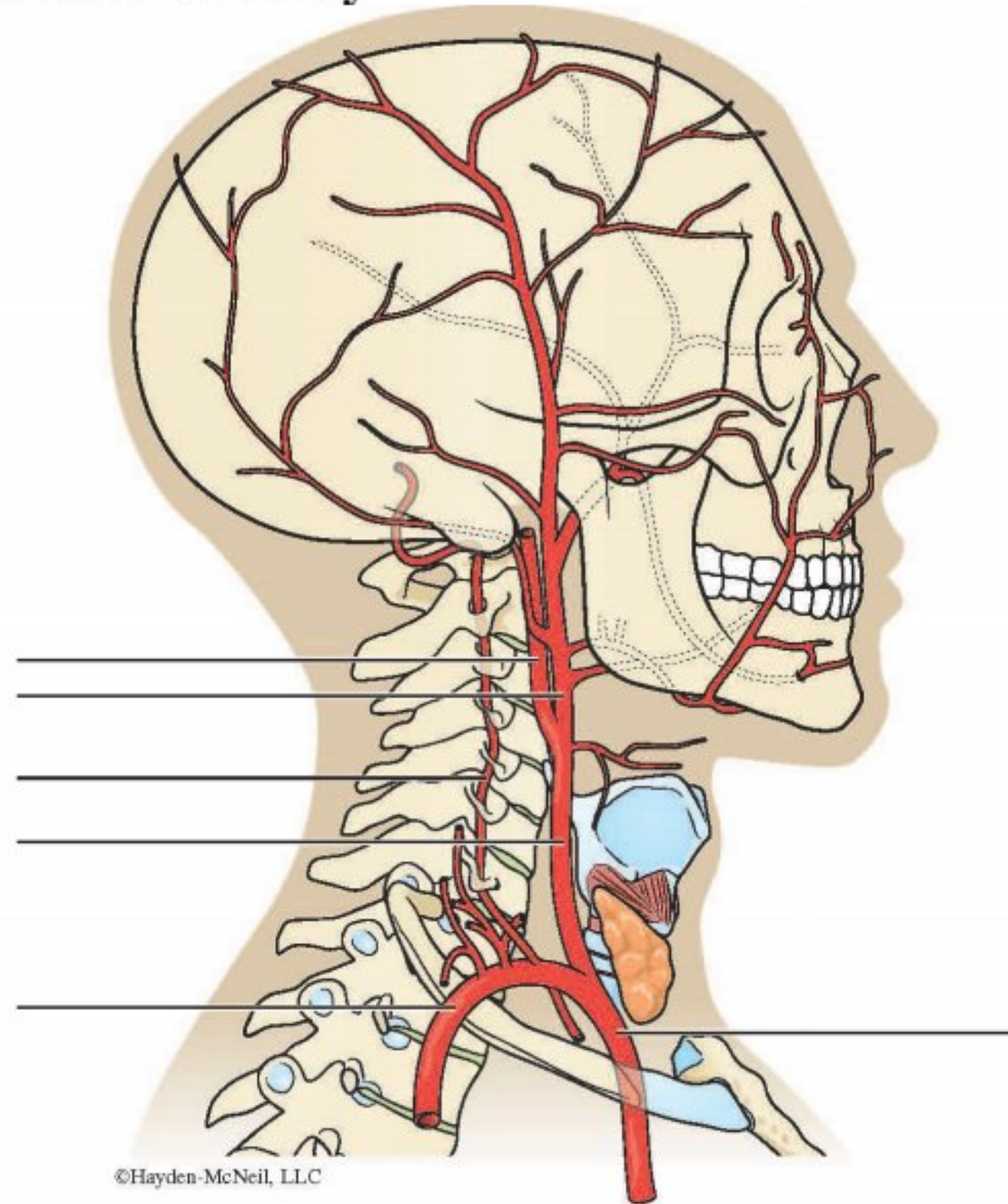
<i>Feature</i>	<i>Artery</i>	<i>Vein</i>
Wall thickness		
Size of lumen		
Thickest tunic layer		
One-way valves		
Blood pressure		

- What is the role of one way valves in the return of blood to the heart? _____

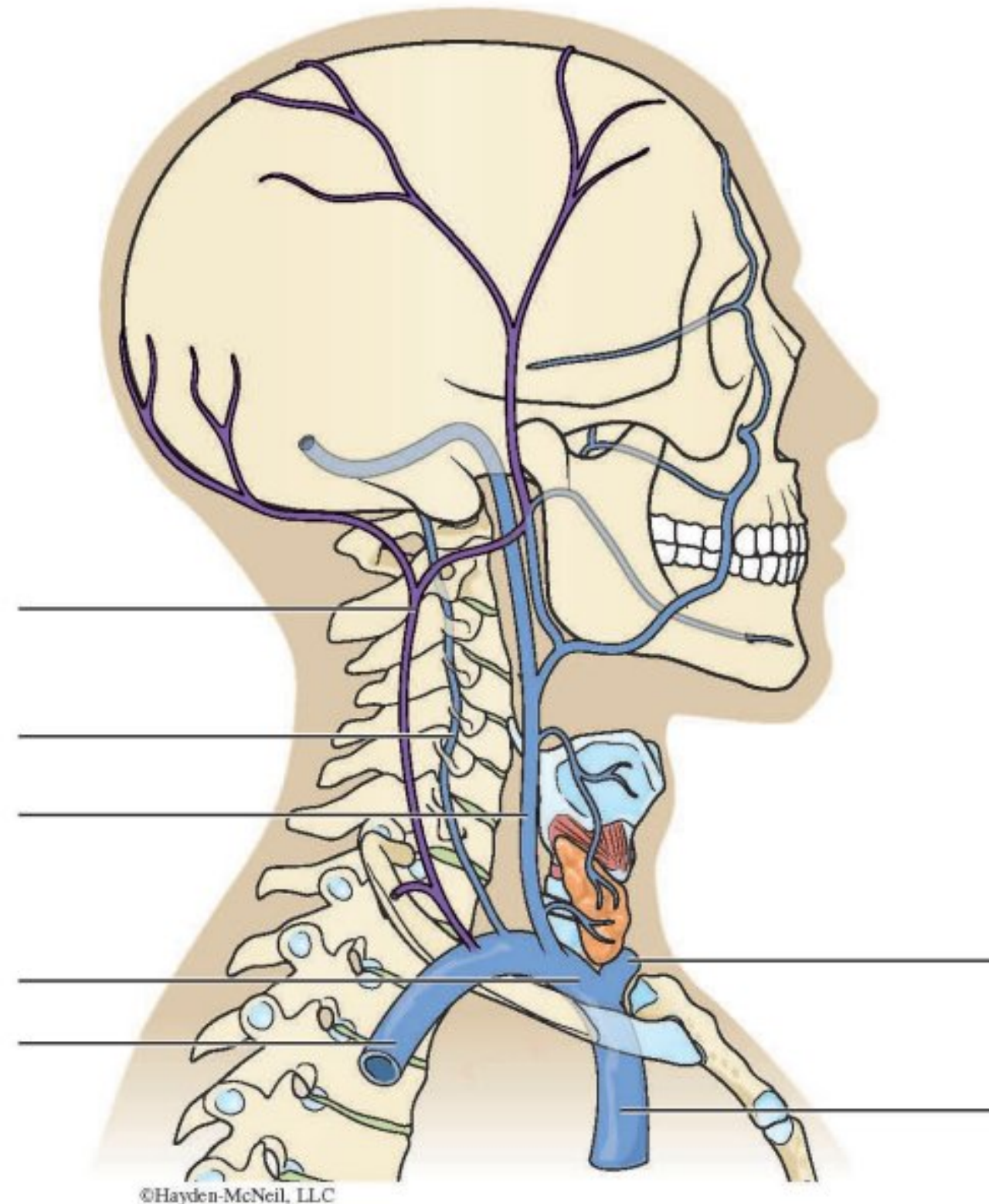
Do all veins have valves? Explain. _____

C. Identification of arteries and veins

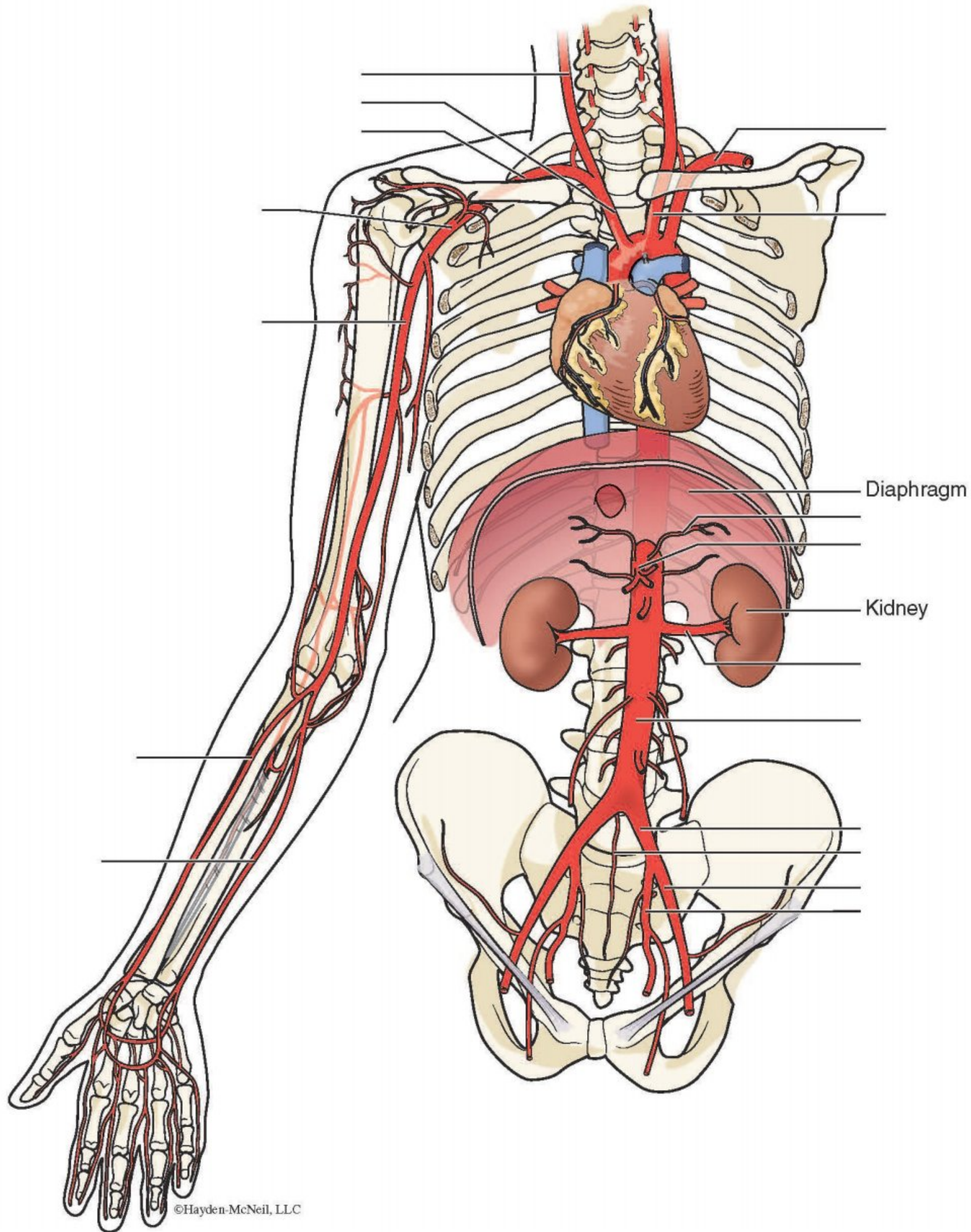
1. Label the specific arteries taking blood to the head and neck region: **vertebral artery, subclavian artery, brachiocephalic trunk, external carotid artery, common carotid artery, internal carotid artery**



2. Label the specific veins bringing blood back from the head and neck region: **right brachiocephalic vein, internal jugular vein, left brachiocephalic vein, vertebral vein, superior vena cava, external jugular vein**

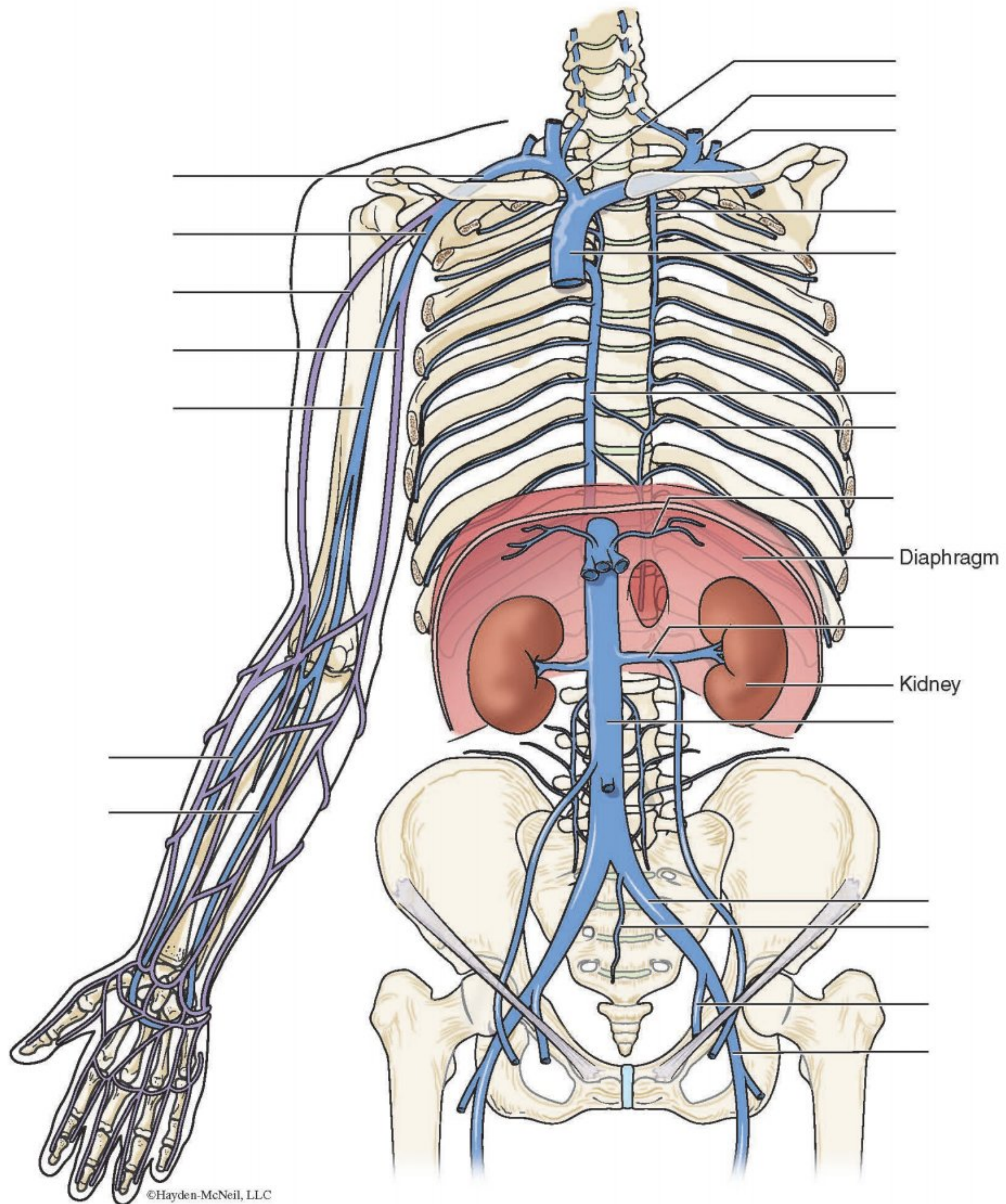


3. Label the specific arteries taking blood to the arm, neck, thoracic and abdominal region:
vertebral artery, right common carotid artery, left common carotid artery, brachiocephalic trunk, right subclavian artery, left subclavian artery, right axillary artery, right brachial artery, right radial artery, right ulnar artery, inferior phrenic artery, celiac trunk, left renal artery, abdominal aorta, left common iliac artery, medial sacral artery, internal iliac artery, external iliac artery



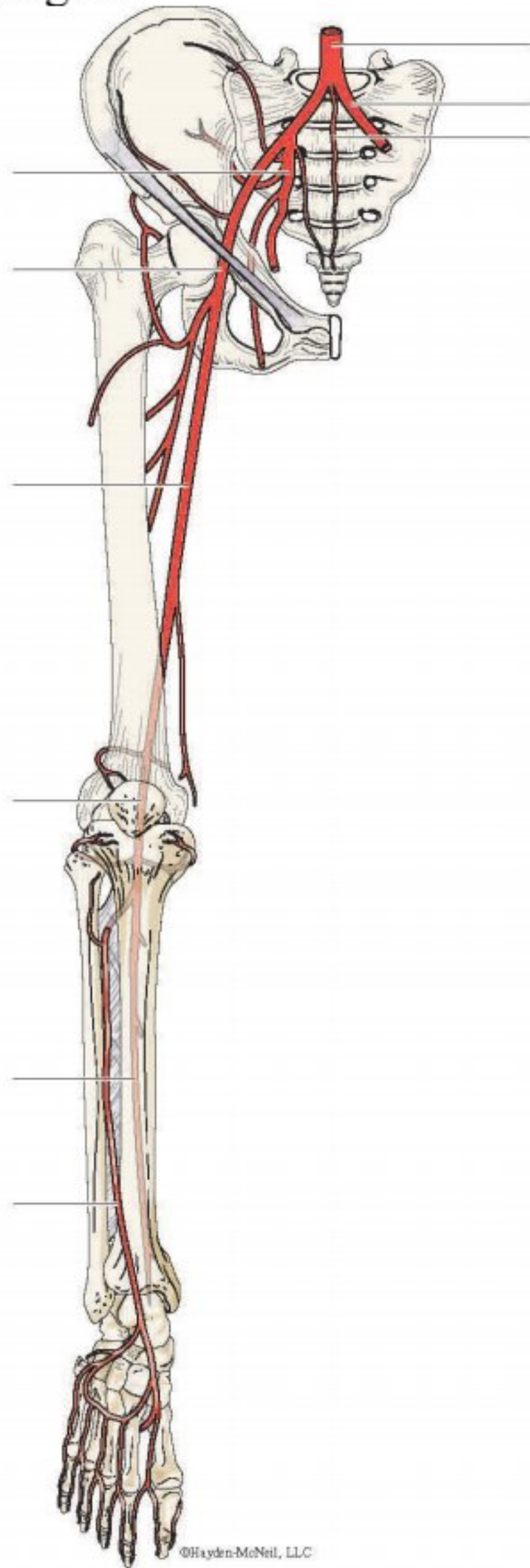
©Hayden-McNeil, LLC

4. Label the specific veins bringing blood back from the arm, neck, thoracic and abdominal region: **brachiocephalic vein, internal jugular vein, hemiazygos vein, superior vena cava, external jugular vein, azygos vein, right subclavian vein, intercostal vein, axillary vein, inferior phrenic vein, cephalic vein, renal vein, basilic vein, inferior vena cava, brachial vein, external iliac vein, radial vein, ulnar vein, internal iliac vein, median sacral vein, external iliac vein**

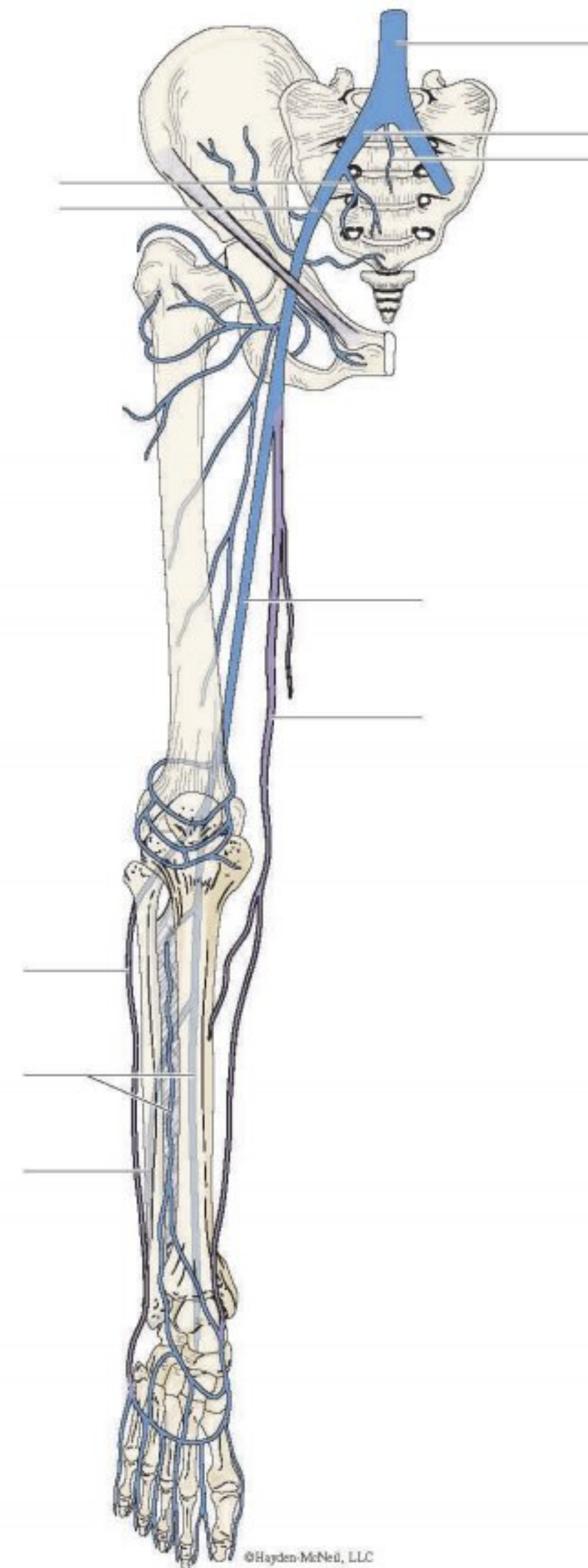


©Hayden-McNeil, LLC

5. Label the specific arteries taking blood into the leg region and veins bringing blood back from the leg region:



External iliac artery, femoral artery, internal iliac artery, popliteal artery, median sacral artery, tibial artery, common iliac artery, fibular artery, abdominal aorta



External iliac vein, great saphenous vein, internal iliac vein, femoral vein, median sacral vein, tibial vein, common iliac vein, fibular vein, inferior vena cava, small saphenous vein



6. Trace the flow of blood from the heart to the right arm using the following terms: **arch of the aorta, ascending aorta, axillary artery, brachial artery, brachiocephalic trunk, radial and ulnar arteries, and subclavian artery**

_____ → _____ → _____ →
 _____ → _____ → _____ →
 _____ →

How is the blood flow different for the left arm? _____

7. Trace the flow of blood from the heart to the leg using the following terms: **abdominal aorta, arch of the aorta, ascending aorta, common iliac artery, external iliac artery, femoral artery, thoracic aorta, and tibial and fibular arteries**

_____ → _____ → _____ →
 _____ → _____ → _____ →
 _____ → _____ →

8. Trace the path of pulmonary circulation starting from the right ventricle and ending in the left atrium. **Pulmonary veins, pulmonary trunk, pulmonary arteries**

Right ventricle → _____ → _____
 → capillaries in the lungs → _____ → left atrium

9. Complete the following table.

Arteries	Supply Blood To
Coronary	<i>Heart wall</i>
Brachial	
Common carotid	
Vertebral	
Intercostal	
Suprarenal	
Common hepatic	
Gastric	
Superior/Inferior mesenterics	
Superior and inferior phrenic	
Common iliac	
Circle of Willis	

Veins	Return Blood From
External jugular	<i>External cranium</i>
Internal iliac	
Pulmonary	
Subclavian	
Hepatic portal veins	
Great saphenous	
Internal jugular	
Coronary sinus	
Renal	
Common iliac	
Mesenteric	
Hepatic	

MAKE THE CONNECTION

1. It is the spring of 2016 and you are a runner from Houston, Texas (near sea level) who has come to Mexico City, Mexico (altitude: 7349 feet above sea level) to train for the Olympics.

Initially, how will the high altitude affect your performance? _____

Describe the physiological changes that will help your body compensate. _____

2. Define hypertension. _____

How does this differ from the transient increase in blood pressure caused by exercise?

In individuals with hypertension, a common symptom is edema, particularly in the lower extremities. Individuals with kwashiorkor, a condition caused by protein malnutrition, often present with a swollen abdomen (edema).

What is edema? _____

Explain why edema is a symptom for both hypertension and kwashiorkor. _____

3. A 65-year-old male patient presents with shortness of breath. He has just returned from a vacation in Australia. He reports that he felt fine while he was on vacation, no trouble with breathing. However, he reports that he developed pain in the left leg the day after he arrived home. The leg pain is gone and now the shortness of breath is his chief complaint. His breathing is rapid (tachypnea). His doctor admits him to the hospital and orders a pulmonary arteriography.

a. What does the doctor suspect is the diagnosis? _____

b. Why is the fact that he just returned from a trip to Australia helpful? _____

c. What was the probable cause of the leg pain? _____

d. How could this problem be avoided? _____



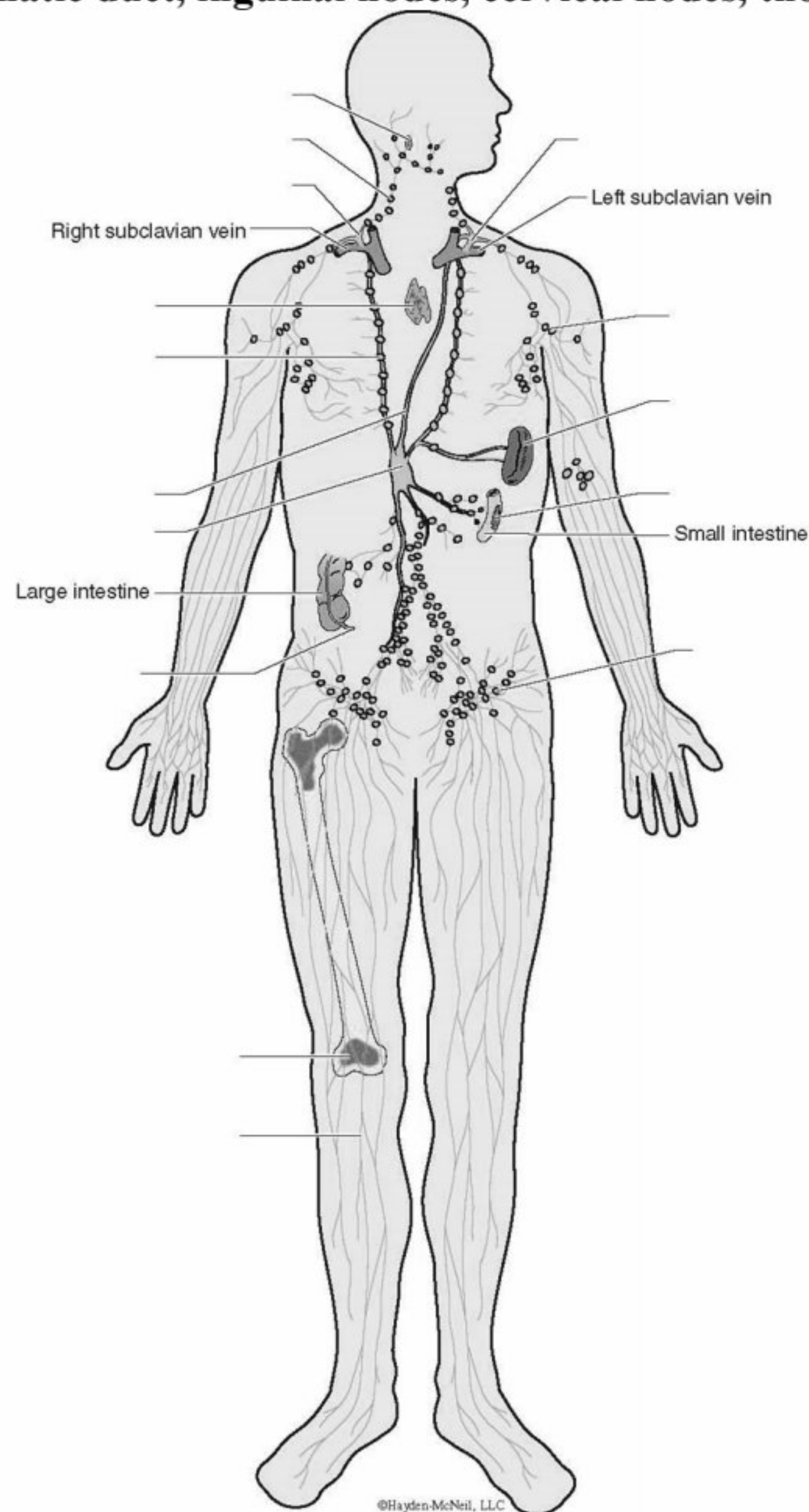
Name: _____

Date: _____

9. The Lymphatic System

A. Anatomy of the lymphatic system

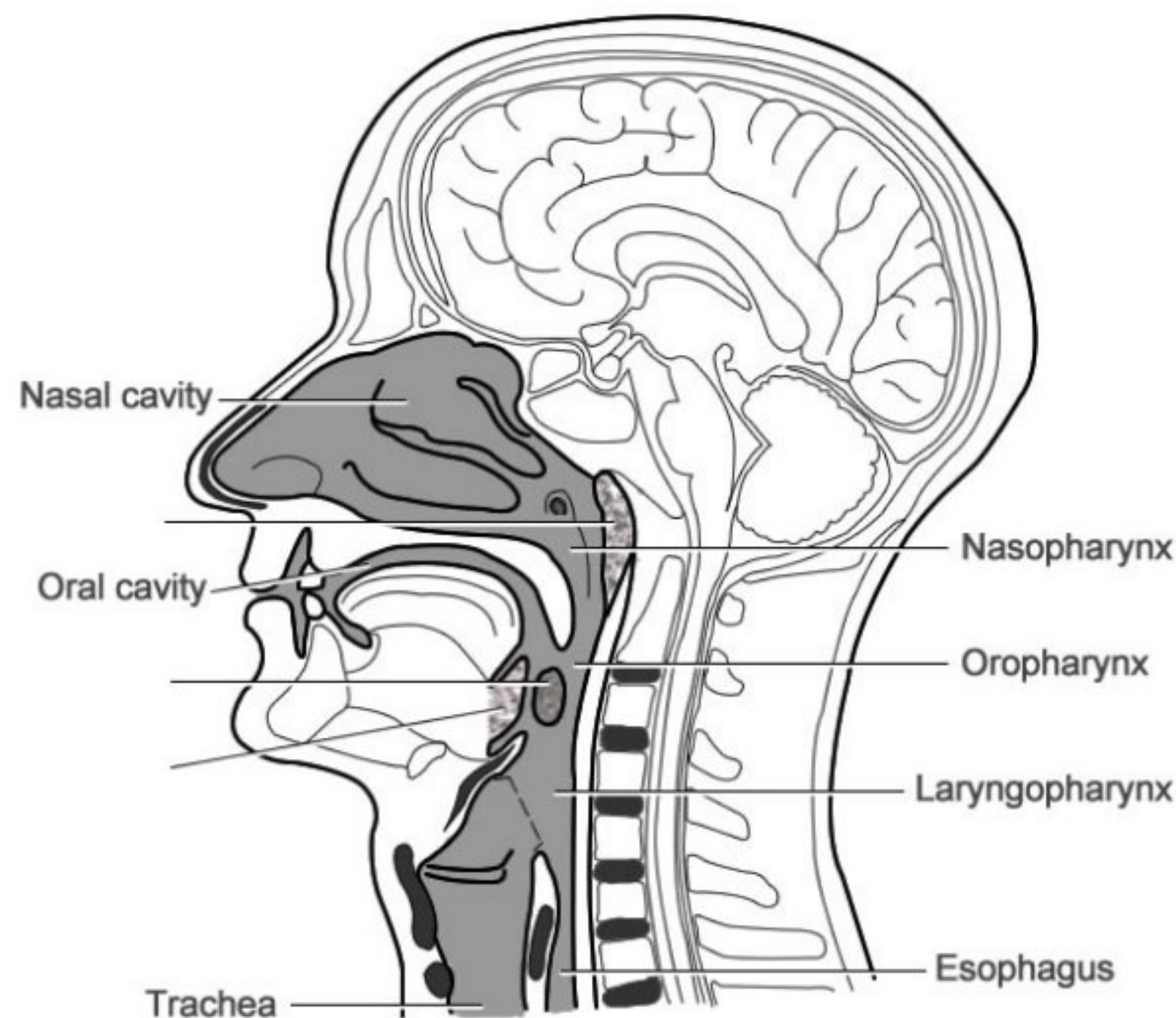
1. Label the lymphatic structures in the network shown below: **bone marrow, lymphatic vessel, appendix, thoracic duct (2), cisterna chyli, axillary nodes, spleen, Peyer's patch, thymus, right lymphatic duct, inguinal nodes, cervical nodes, thoracic nodes, tonsil**



2. Trace the flow of lymph from its formation until it enters the blood: **lymphatic trunks, tissue fluid, lymphatic vessels, lymph nodes, lymphatic capillaries, subclavian veins and lymphatic ducts**

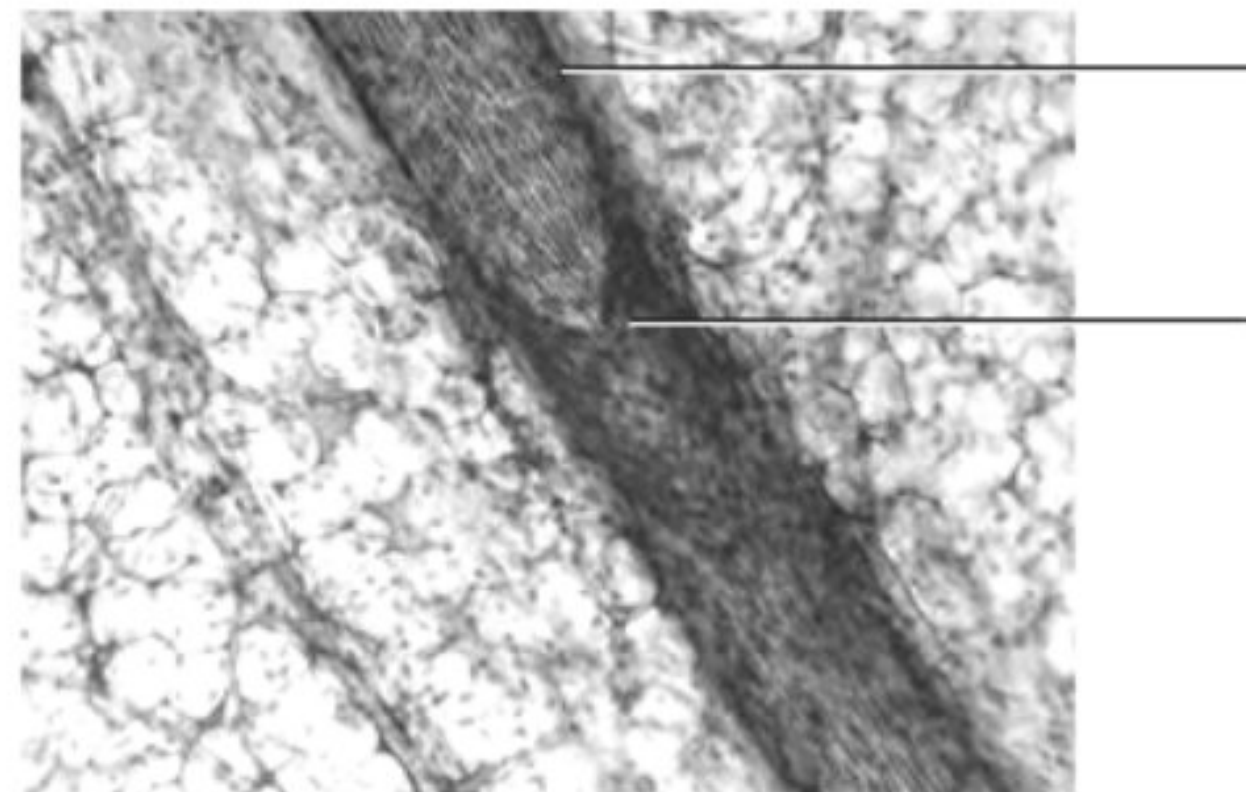
_____ → _____ → _____
 → _____ → _____ → _____
 → _____

3. The right lymphatic duct is connected the _____ vein and thoracic duct is connected to the _____ vein.
4. Label the tonsils and specific areas they are located in: **pharyngeal tonsil, lingual tonsil, palatine tonsil**



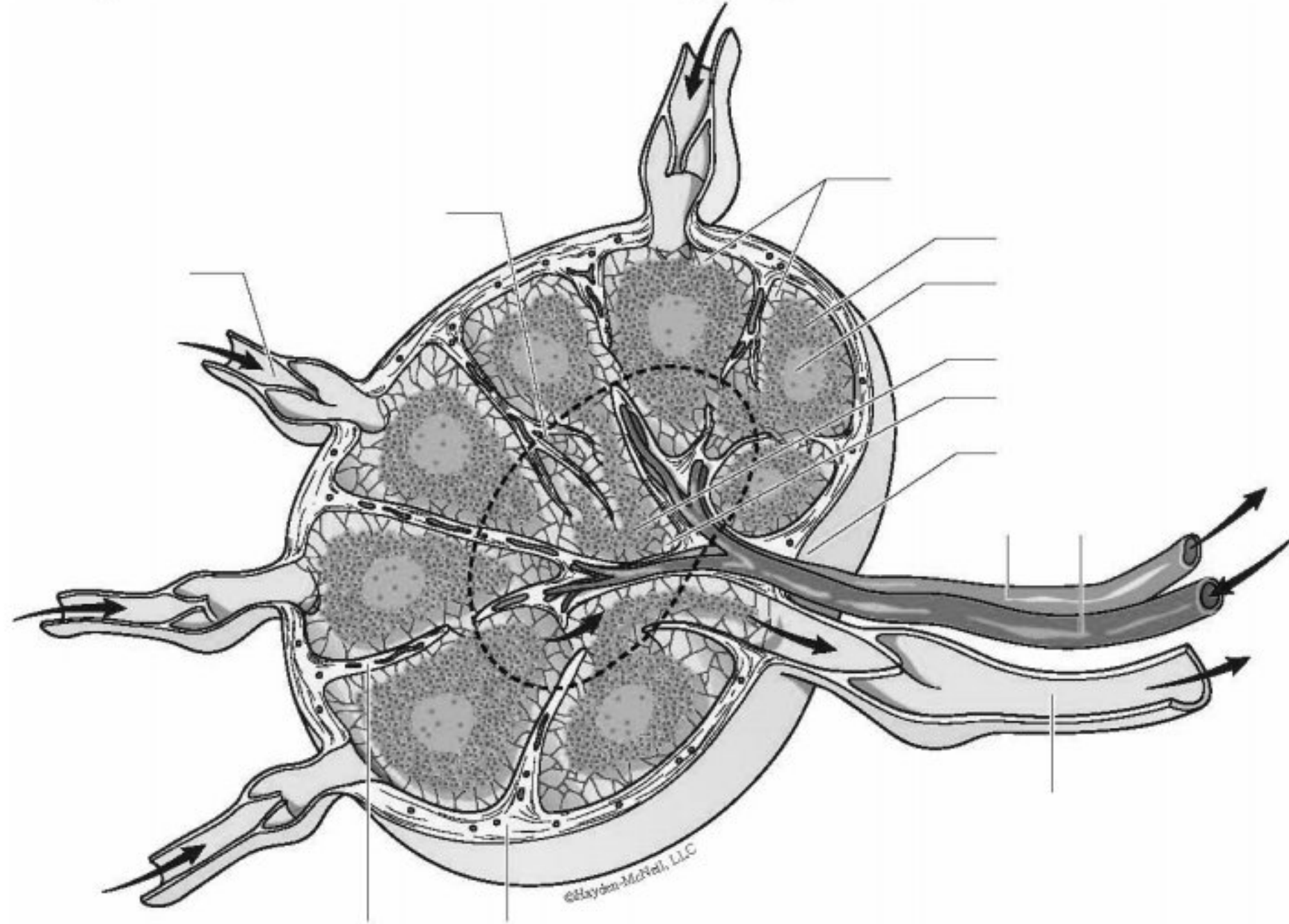
B. Histology of the lymphatic system

1. Label the lymphatic vessel micrograph: **lymphatic vessel, one-way valve.**



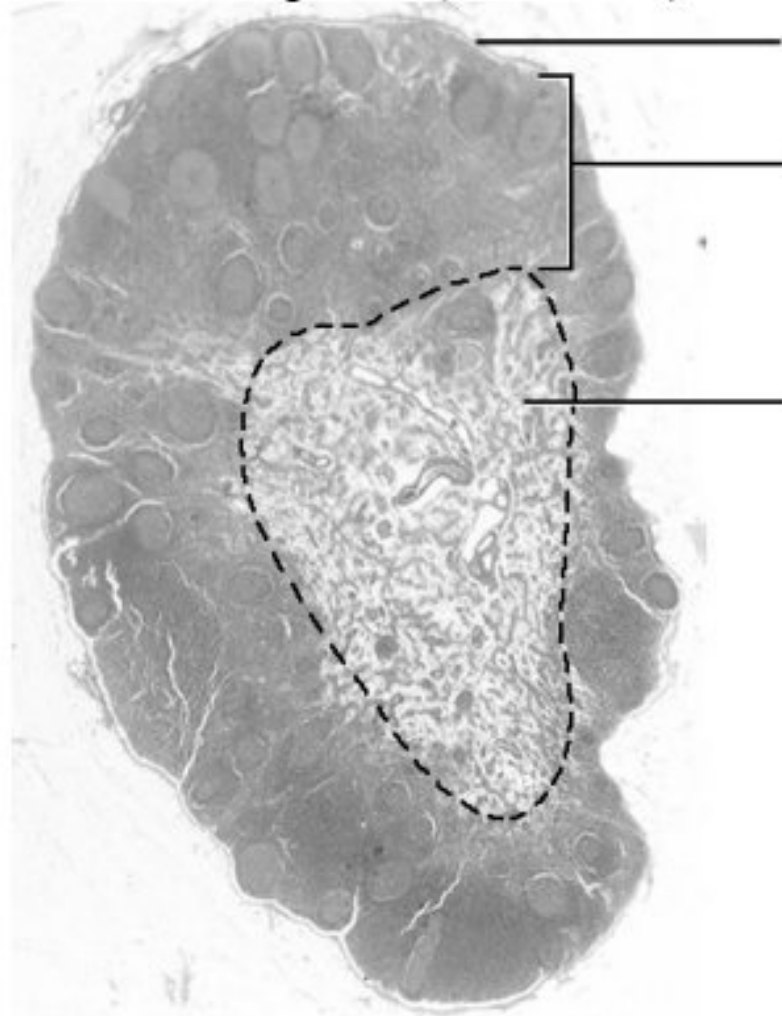
What is the role of one-way valve in lymphatic system?

2. Label the parts of a lymph node: **hilum, capsule, medullary cord, cortical sinus, germinal center, lymphatic nodule, medullary sinus, efferent lymphatic vessel, afferent lymphatic vessels, artery, vein, trabecula, medullary region**

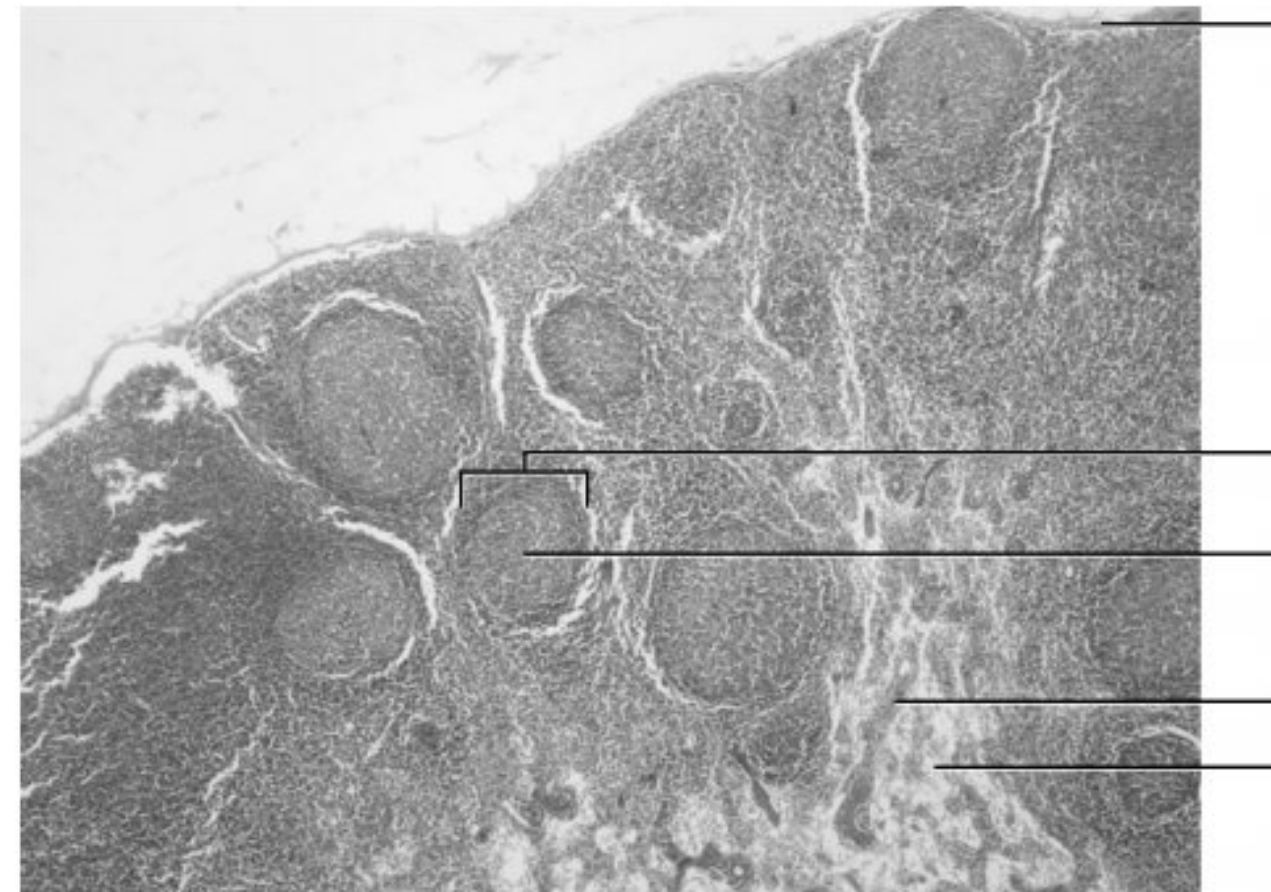


3. Label the specific parts seen in lymph node micrograph:

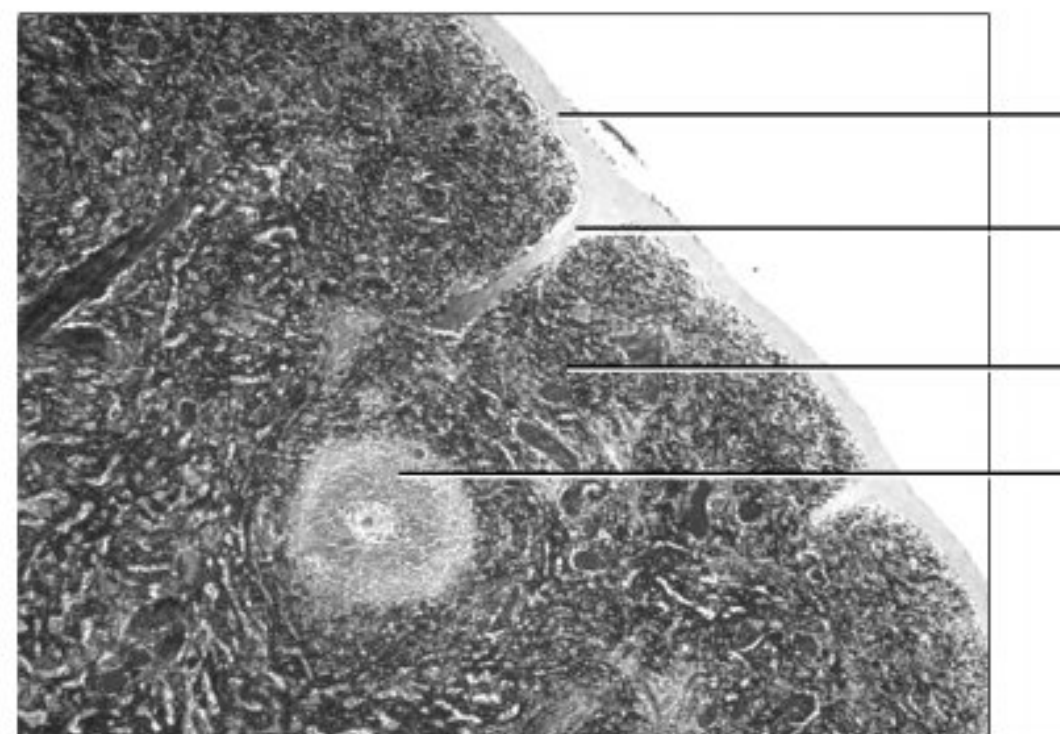
Label: **capsule, cortex, medulla**



Label: **capsule, medullary cord, germinal center, lymphatic nodule, medullary sinus**



4. Label the parts seen in spleen micrograph: **capsule, trabecula, white pulp and red pulp.**



5. Compare the composition and functions of the red and white pulp of the spleen.

Red pulp: _____

White pulp: _____

6. Complete the following table with information on two types of specific immunity..

	Cell-mediated Immunity	Antibody-mediated Immunity
Types of lymphocytes involved:		
Site of lymphocyte maturation:		
Mode of action:		

MAKE THE CONNECTION

1. Explain the role that the lymphatic system plays in the metastasis of cancer.

2. A 16-year-old female patient with a history of tonsillitis 4 weeks before coming to the clinic presents to a physician with arthritis that has been moving from joint to joint (migratory polyarthritis). An echocardiogram reveals that the mitral valve is damaged and a sedimentation rate indicates the patient has acute inflammation which is later traced to the heart muscle.

Follow the sequence of events which explains how tonsillitis led to polyarthritis and damage of the heart. _____

3. What is splenectomy? _____

Give two main reasons why this surgery may be performed: _____

How will this surgery affect body's protection and supply of blood cells? _____

Pre-Lab

Name: _____

10. *The Respiratory System*

1. The nasal cavity is separated from the oral cavity by the hard and soft _____.
The cartilaginous flap at the opening of the larynx that prevents the entry of food into the lower respiratory system is called the _____.
The posterior wall of the trachea is made up of a smooth muscle called the _____.
2. The lungs are located in the _____ cavity.
3. The lungs are surrounded by a double serous membrane called the _____. The inner membrane that touches the lung is the _____ while the outer membrane that touches the inside of the thoracic cavity is the _____.
4. There are _____ lobes in the right lung and _____ lobes in the left lung. This means that there are _____ secondary bronchi on the right and _____ secondary bronchi on the left.
5. The type of cell in the alveoli through which gas exchange takes place is called a(an) _____; the type of cell which gets rid of pathogens or debris is called a(an) _____ and the type of cell that produces surfactant is called a(an) _____.
6. Name the primary muscles involved in quiet inspiration. _____
7. The two regions of the brain stem that control the breathing rate are the _____ and the _____.



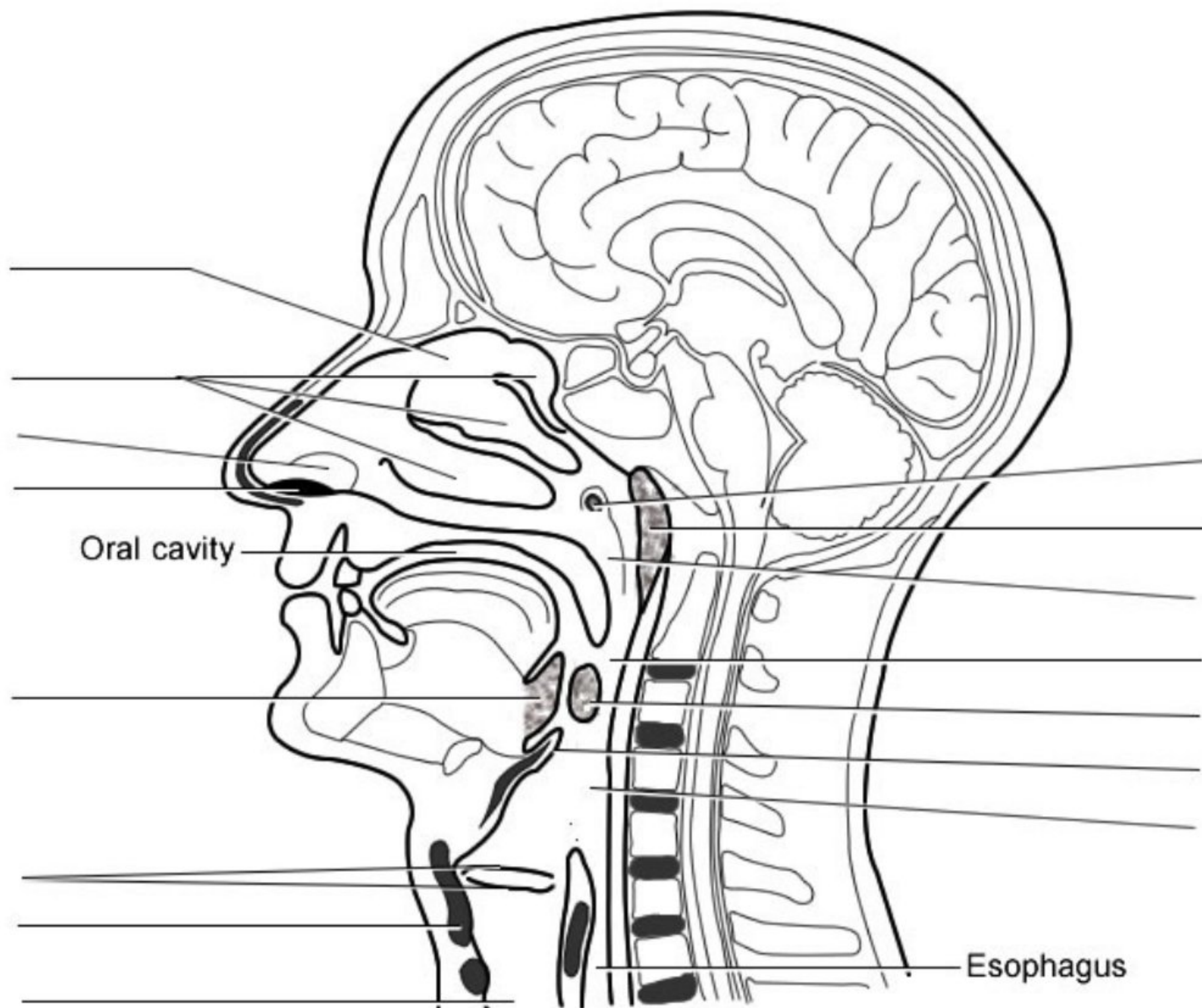
Name: _____

Date: _____

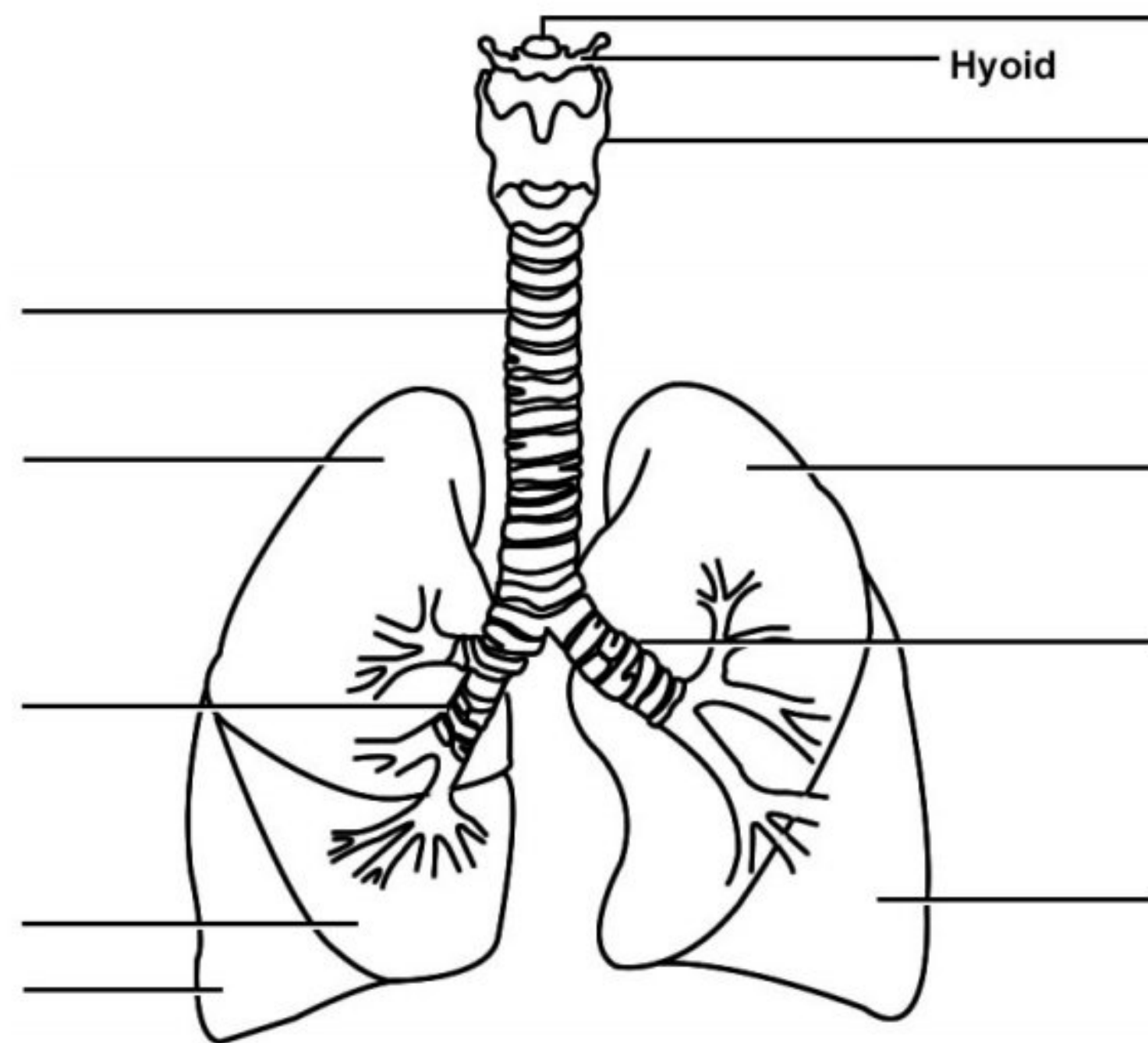
10. *The Respiratory System*

A. Anatomy of the respiratory system

1. Label the parts of the upper respiratory system: **conchae, epiglottis, external naris, laryngopharynx, nasal cavity, nasopharynx, lingual tonsil, opening of eustachian tube, oropharynx, palatine tonsil, thyroid cartilage, trachea, vocal folds, pharyngeal tonsil, nasal vestibule**



2. Label the parts of the lower respiratory system: **epiglottis, inferior lobe of left lung, inferior lobe of right lung, larynx, middle lobe of right lung, primary bronchus, secondary bronchus, superior lobe of left lung, superior lobe of right lung, trachea**



3. Fill in the blanks with the parts of the conducting zone in the correct sequence: **glottis, nasopharynx, larynx, nasal cavity, trachea, laryngopharynx, internal nares, bronchi, bronchioles**

Nostril → _____ → _____
 → _____ → oropharynx → _____ →
 _____ → _____ → _____ → _____
 → _____

4. List the parts of the respiratory zone in the correct sequence: **alveolar ducts, alveoli, respiratory bronchioles, alveolar sacs**

_____ → _____ → _____ →

5. Name the three divisions of the pharynx and the type of epithelial tissue that lines each region. How does the epithelium of each relate to its function?

Div. of pharynx	Type of epithelium	Relate epithelium to function

6. List the types of changes that take place for the following characteristics, when going from the trachea to the alveoli.

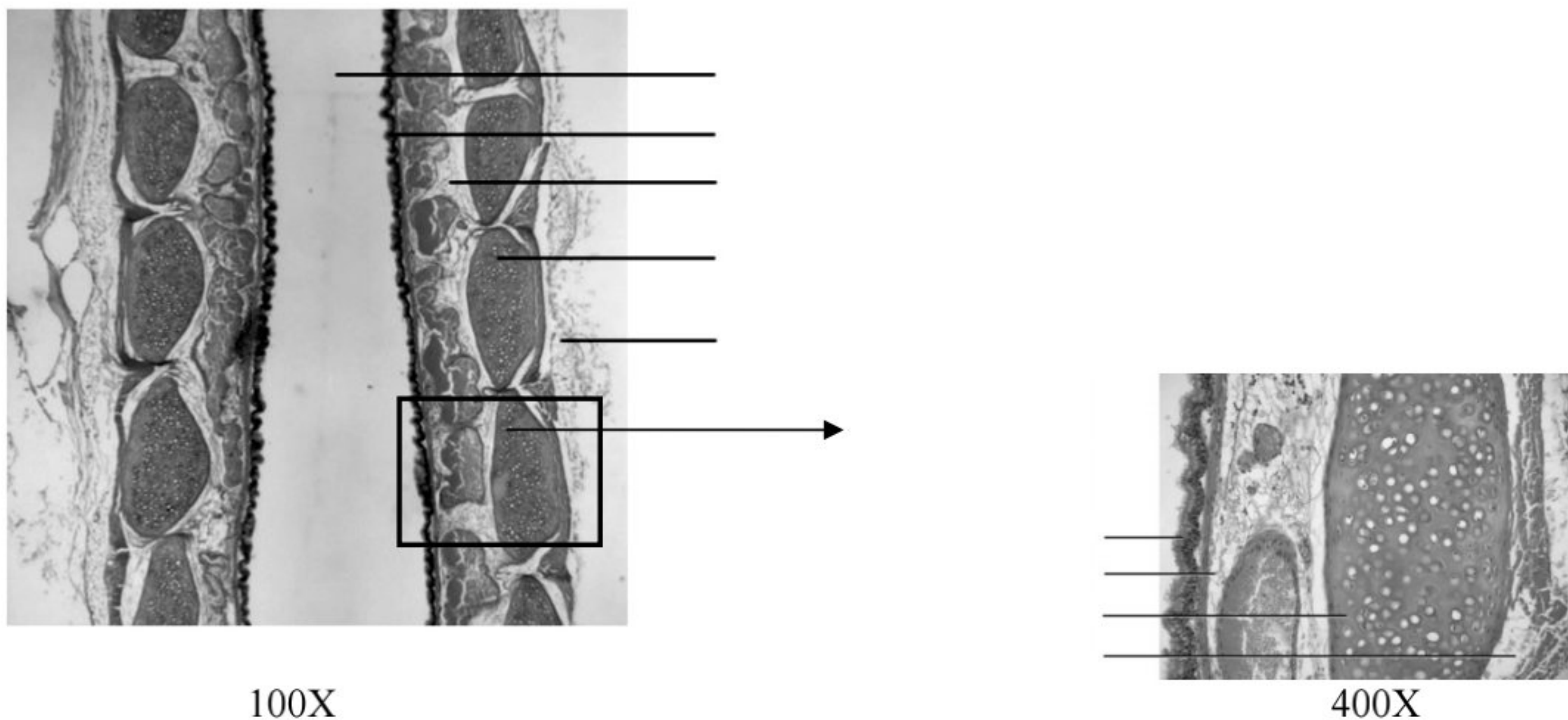
Characteristic	Change
Size of tube	
Thickness of wall	
Cartilage	
Smooth muscle	
Type of epithelium	

7. Using the table below, list the muscles involved in breathing.

Situation	Muscle(s) involved
Normal/quiet inhalation	
Normal/quiet exhalation	
Forced inhalation	
Forced exhalation	

B. Histology of the respiratory system

1. Identify the structures in these photomicrographs of the tracheal wall: **adventitia, cartilage, lumen, mucosa, submucosa**

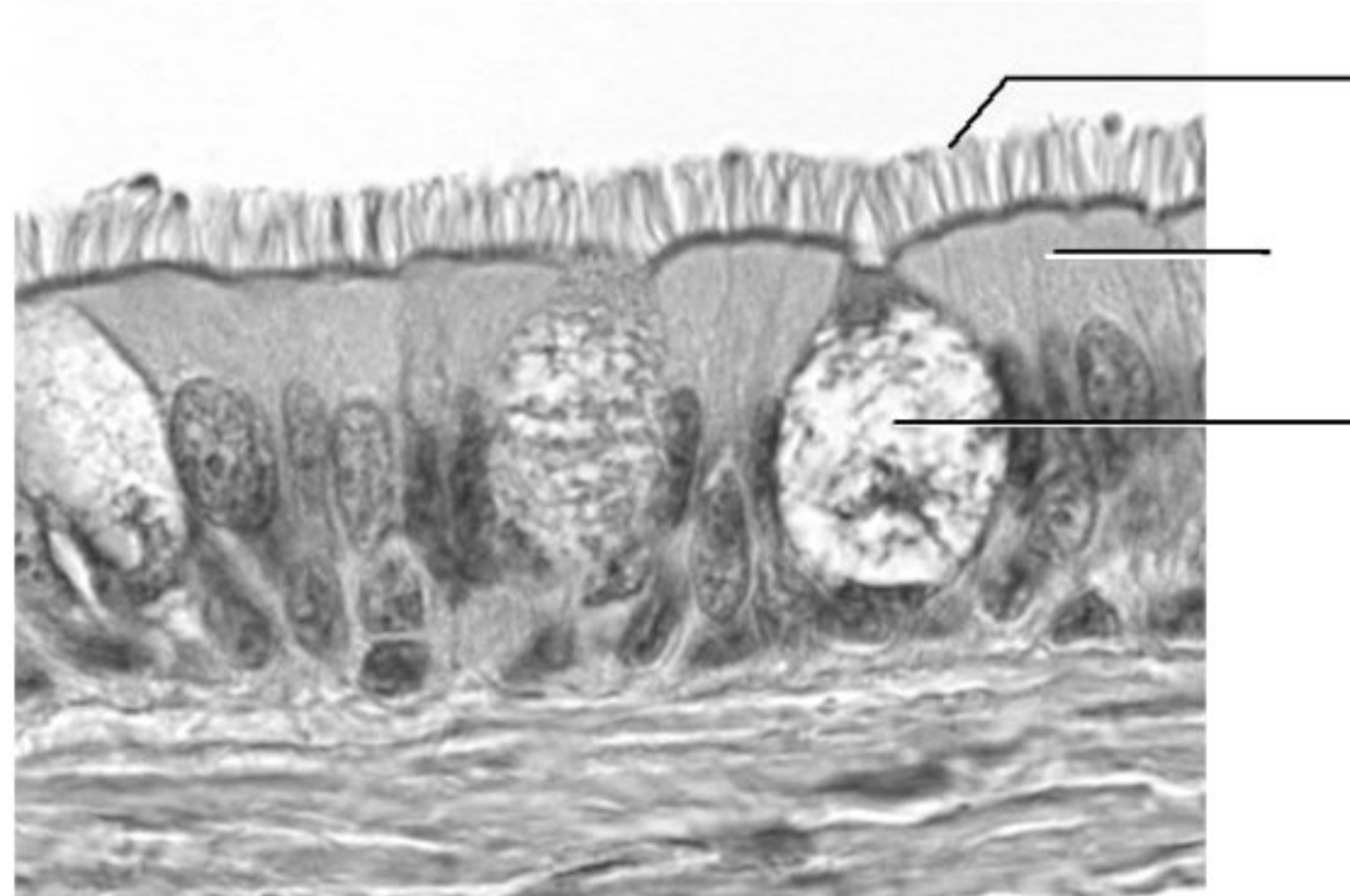


2. Why is the trachea supported by cartilage? _____

Why are these rings incomplete? _____

What is the function of trachealis muscle? _____

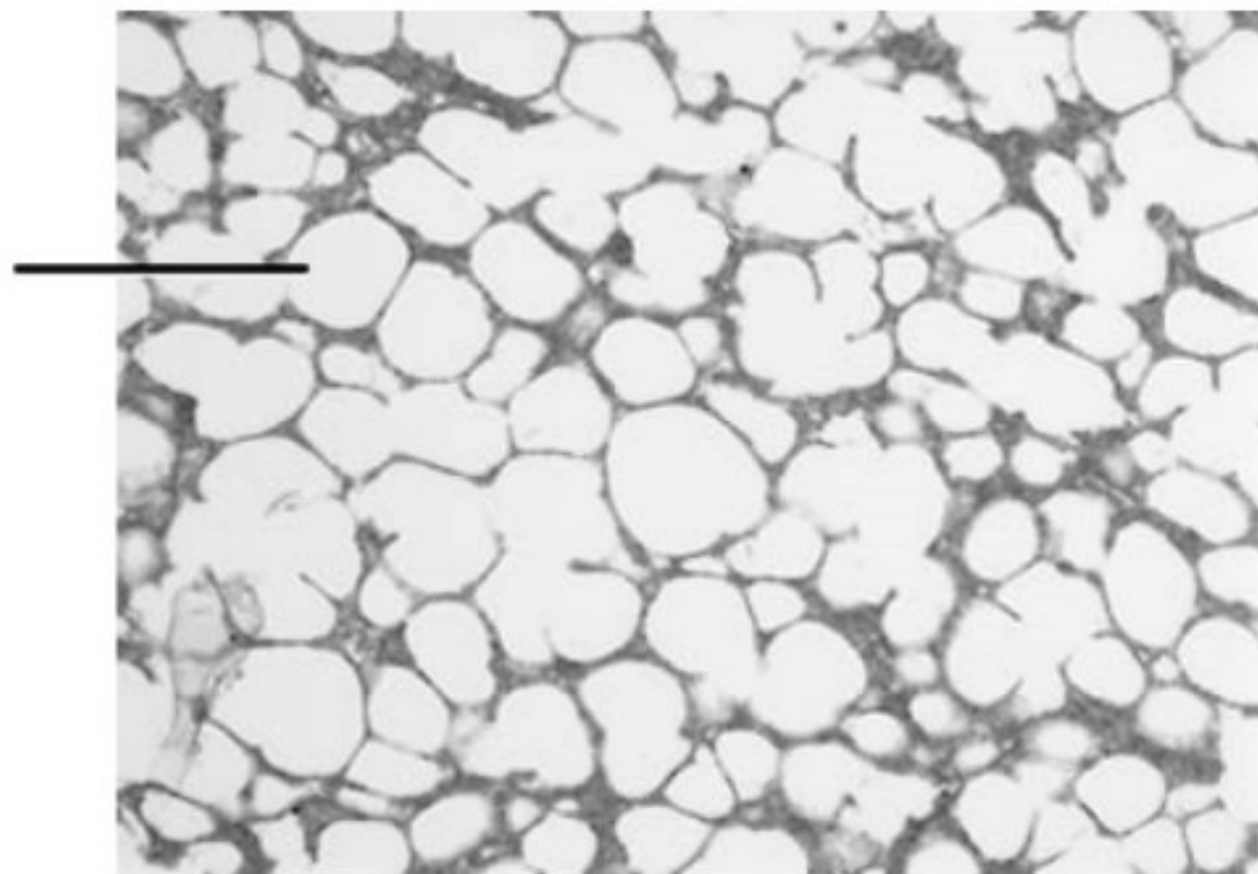
3. Identify the structures in this photomicrograph of the tracheal mucosa: **columnar epithelial cells, cilia, goblet cell**



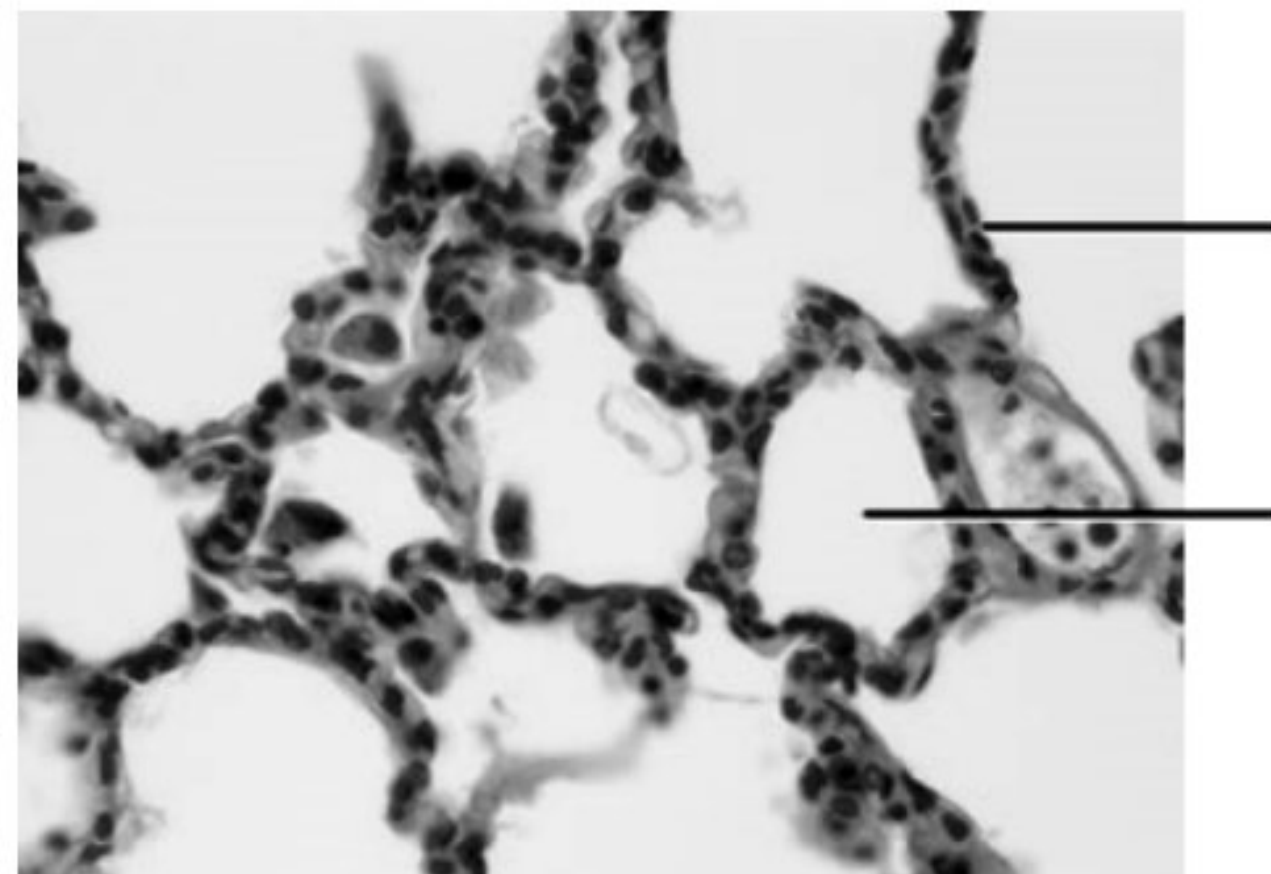
What is the function of the goblet cells in the wall of the trachea?

Why are epithelial cells lining the trachea have cilia?

4. Label the parts in the section of a normal lung: **alveolar space, alveolar wall**

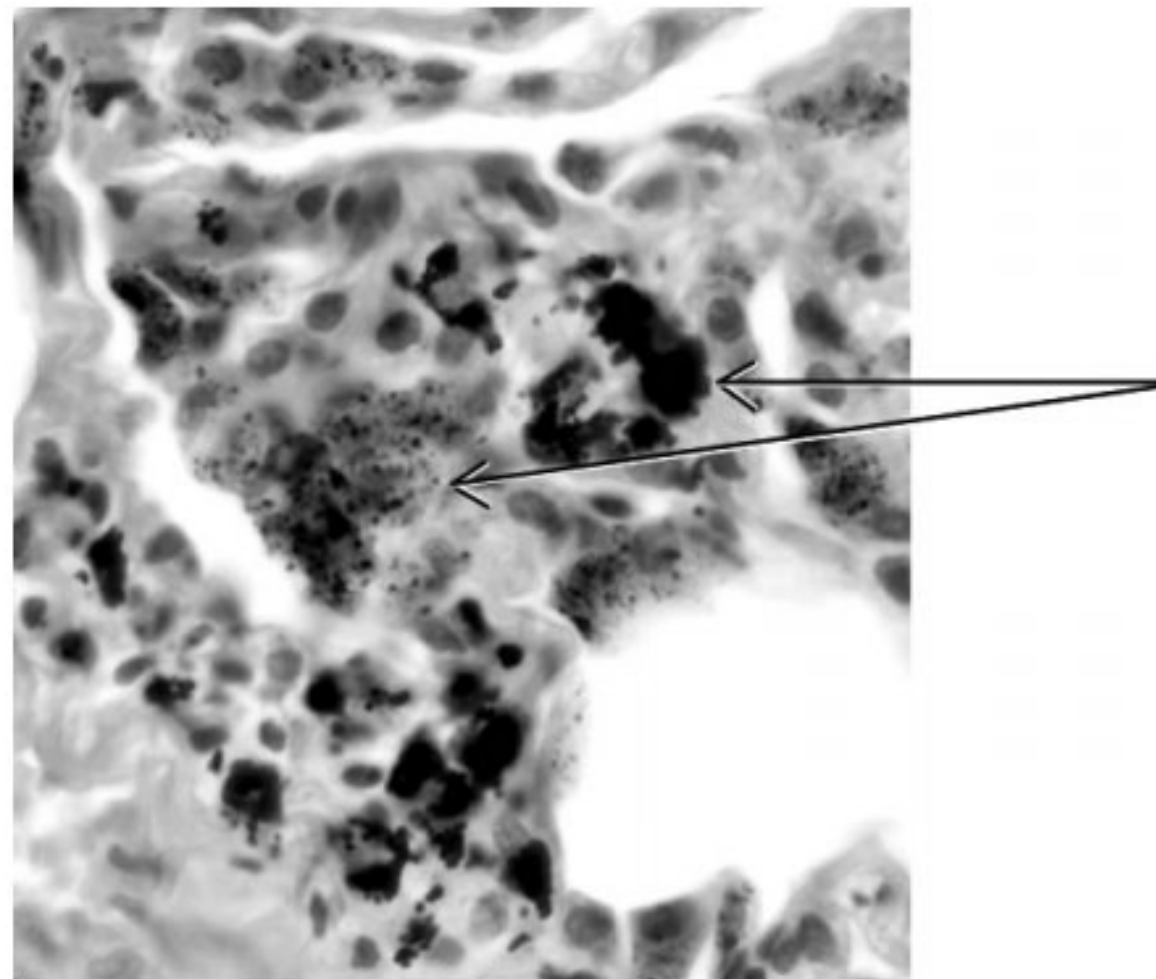


Normal lung (100X)



Normal lung (400X)

5. Observe the slide of the lung with anthracosis: **carbon particles**



400X

Describe the structural and functional differences between normal lung vs. lung exhibiting anthracosis.

MAKE THE CONNECTION

1. Donna and James have a son named Daniel who is four months old. As is often the case with young children who go to daycare, Daniel keeps getting colds. His pediatrician has listened to Daniel's chest and even though he sometimes wheezes when coughing, the pediatrician thought it was simply a cold. A few days later, Daniel's condition had worsened and Donna and James brought him to the emergency room. Upon auscultation, the emergency room physician heard coarse rattling sounds in Daniel's lungs and noted salt crystals on his skin. A pediatric pulmonologist was called in and informed Daniel's parents that their child has cystic fibrosis. Read about cystic fibrosis in your text and online then answer the following questions.

What is cystic fibrosis? _____

Which organ systems are affected by this disorder? _____

Why is the mucus so thick and how is it expelled from the respiratory tract?

Is there a genetic implication for this disorder? _____

Pre-Lab

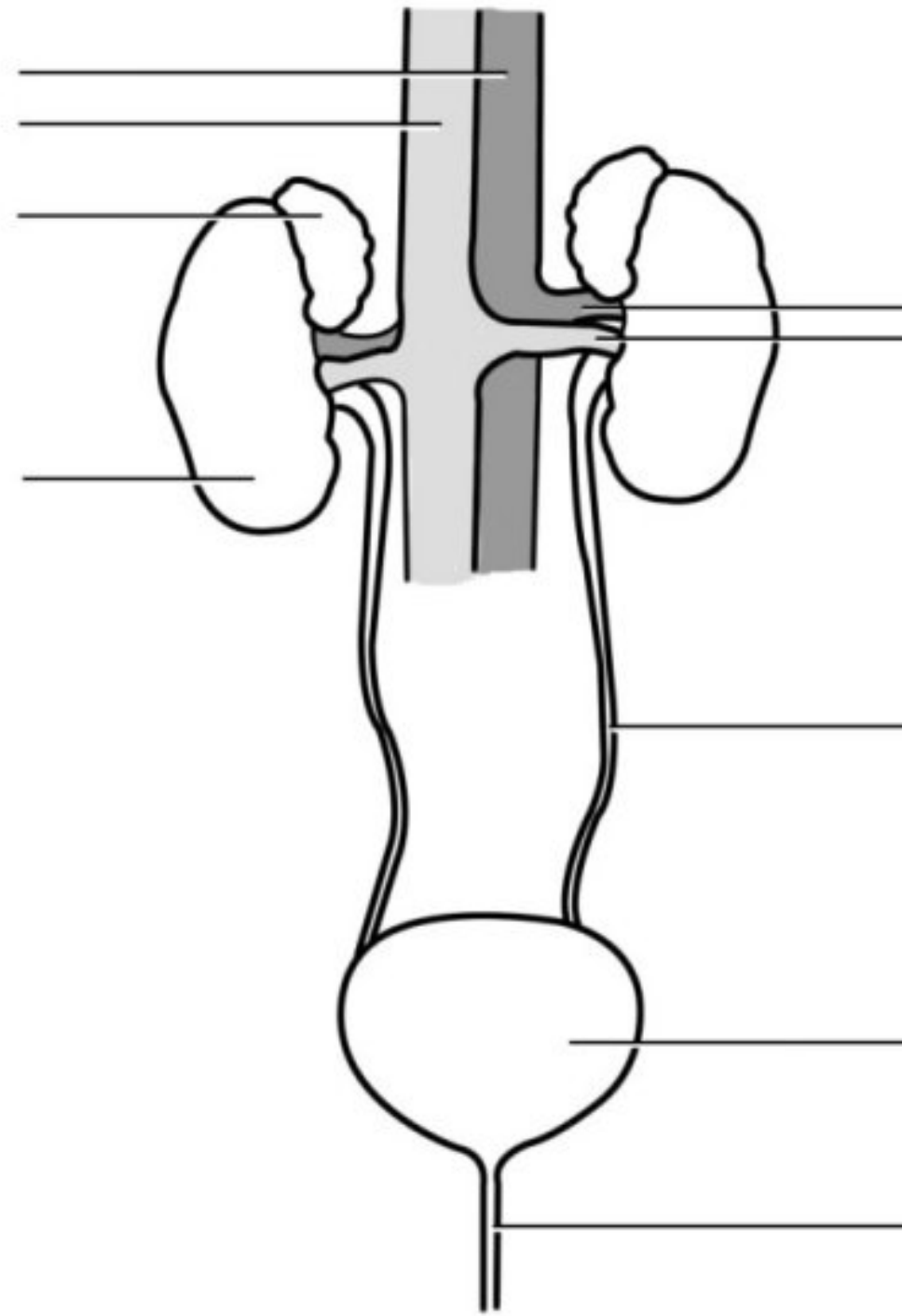
Name: _____

11. The Urinary System

1. Give four functions of the urinary system.

- a. _____
- b. _____
- c. _____
- d. _____

2. Label the drawing of the urinary system: **adrenal gland, aorta, inferior vena cava, kidney, renal artery, renal vein, ureter, urinary bladder, urethra**



3. Complete the following table for the function of the components of the urinary system.

Part	Function
Kidneys	
Ureter	
Urinary bladder	
Urethra	
Renal artery	
Renal vein	



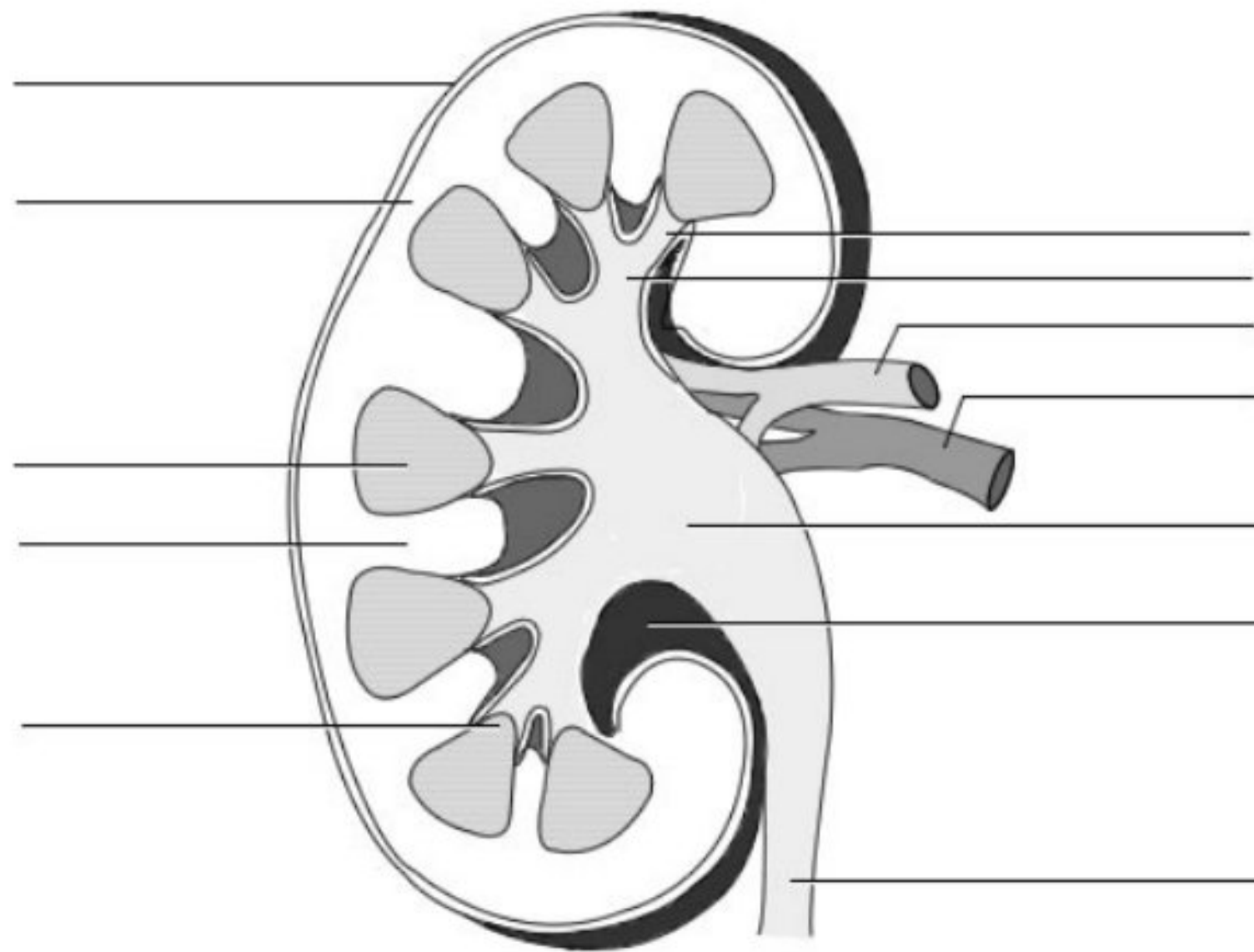
Name: _____

Date: _____

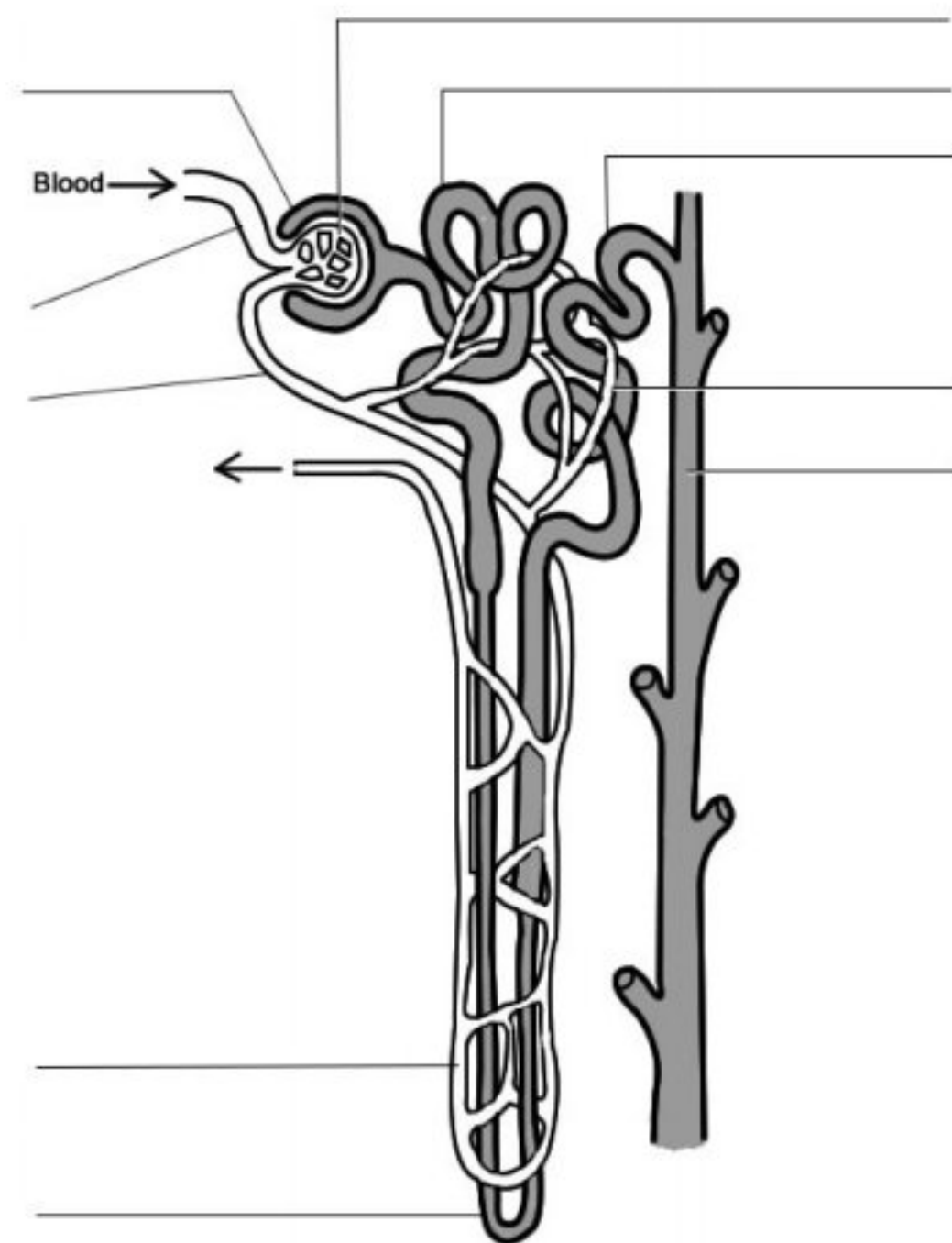
11. The Urinary System

A. Anatomy of the urinary system

1. Label the parts of the kidney using these terms: **capsule, cortex, major calyx, medullary pyramids, minor calyx, renal sinus, renal pelvis, renal column, ureter, renal artery, renal papilla, renal vein**



2. Label the parts of a nephron and of the associated blood vessels: **afferent arteriole, Bowman's capsule, collecting duct, distal convoluted tubule, efferent arteriole, glomerulus, Loop of Henle, peritubular capillaries, proximal convoluted tubule, vasa recta**



3. Name the two types of nephrons found in a human kidney and you see on the kidney plaque. Describe their role in water regulation.

a. _____

b. _____

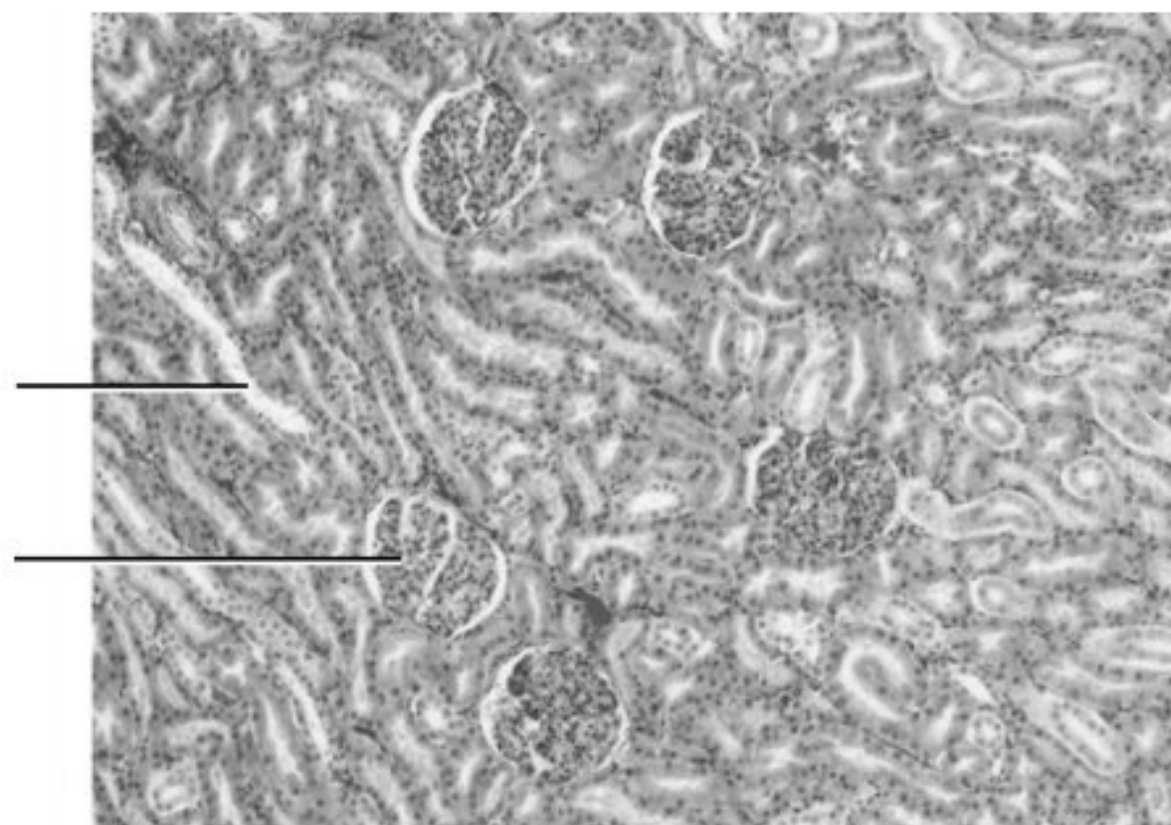
4. Name the two sets of capillaries that are part of the portal system found in the kidneys? What is their specific role in urine formation?

a. _____

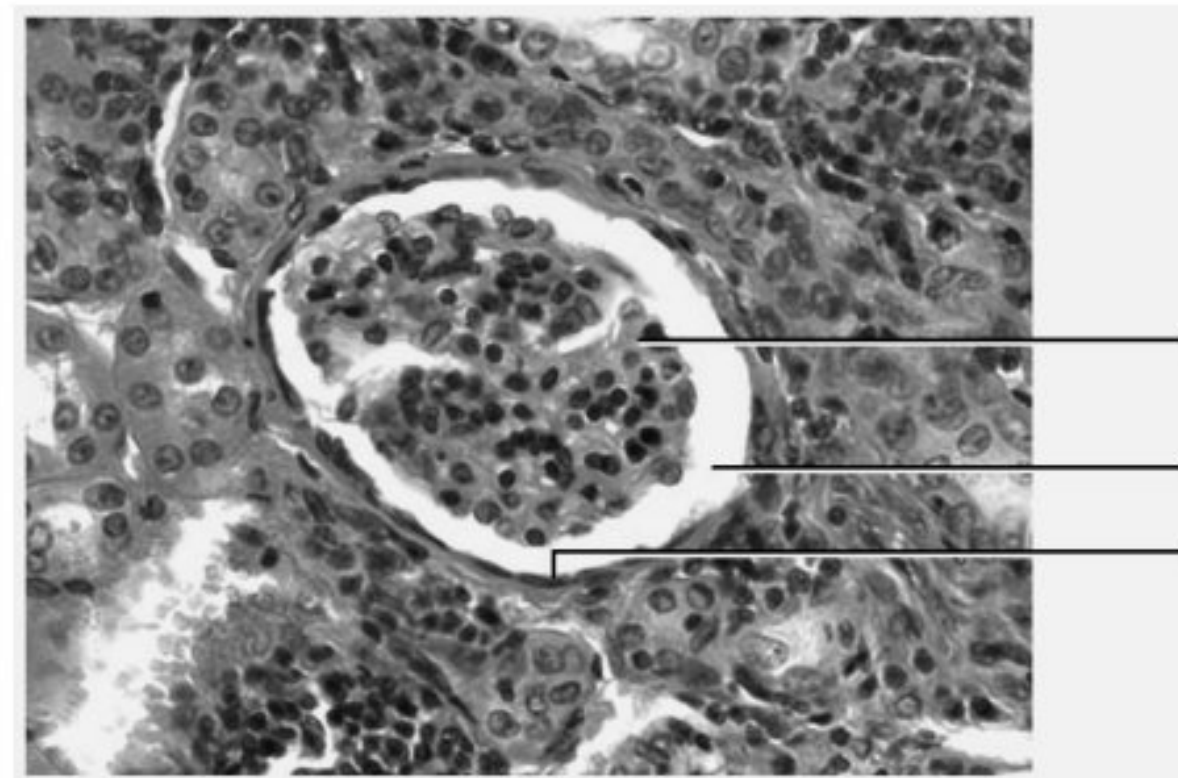
b. _____

B. Histology of the urinary system

1. Label the components of a nephron that you can see in the kidney: **renal corpuscle, tubule, capsular space, glomerulus, parietal wall of glomerular capsule**



100X

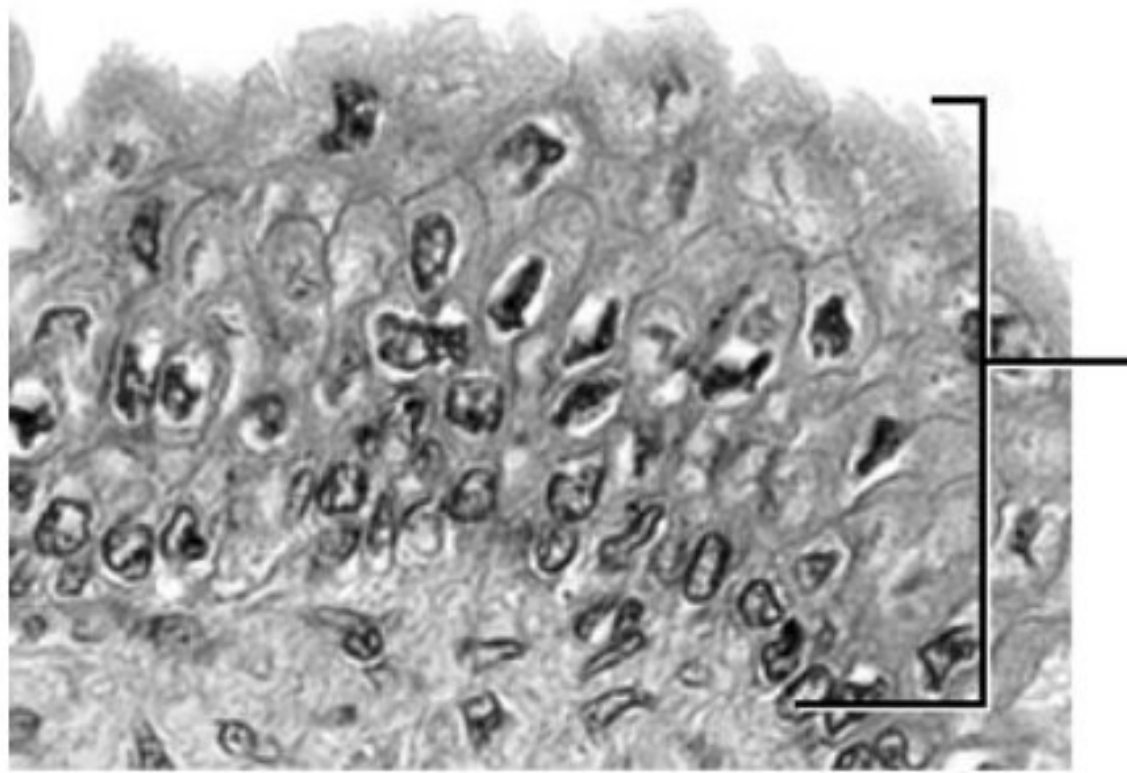


400X

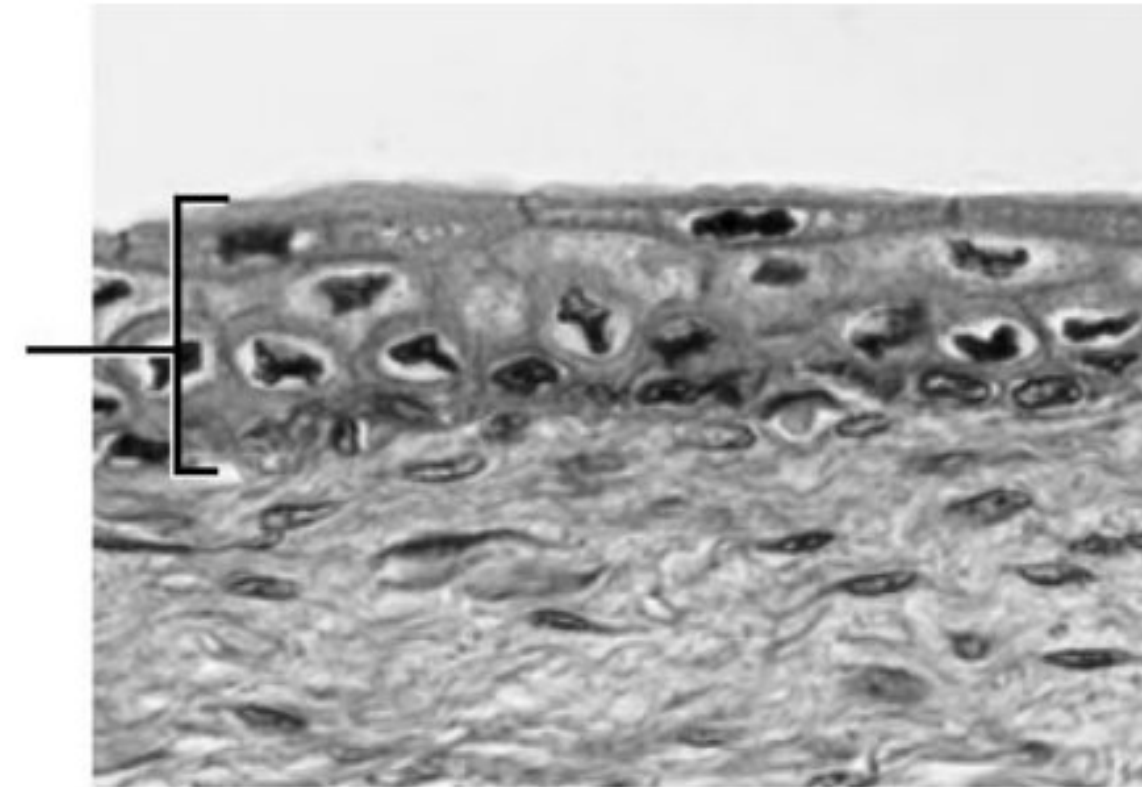
2. For each of the following parts of the nephrons list the specific step of the urine formation that takes place at the site.

Part of the nephron	Step of urine formation
Glomerular capsule	
Proximal convoluted tubule	
Loop of Henle	
Distal convoluted tubule	
Collecting duct	

3. Name the type of the epithelium lining the urinary bladder.



Relaxed urinary bladder



Distended urinary bladder

Compare the epithelium of the relaxed and distended urinary bladder. What difference do you notice?

MAKE THE CONNECTION

1. Why, when a surgeon is operating on the kidney, is the surgery performed from the side/posterior part of the abdomen and not through the anterior abdominal wall?

2. Kidney stones are usually located in the renal pelvis. What affect would this have on urine flow and contents? Why are they so painful?

What is the most common composition of kidney stone?

3. Imagine that you had two large cups of coffee before you left for work. Now you are on the highway, there is an accident ahead, and you have been sitting in traffic in your car for two hours. What is the condition of the rugae in your urinary bladder?

After urine is produced and stored in the urinary bladder, it is not reabsorbed into the body. What prevents the reabsorption? _____

Pre-Lab

Name: _____

13. The Digestive System

1. List the following organs in sequence from mouth to anus: **caecum, colon, duodenum, esophagus, ileum, jejunum, laryngopharynx, oral cavity, oropharynx, rectum, stomach**

Mouth → _____, → _____ → _____
→ _____ → _____ → _____
→ _____ → _____ → _____
→ _____ → _____ → anus

2. Beginning with the innermost layer, name the four layers of the wall of the GI tract:

3. Compare the two types of digestions.

Mechanical: _____

Chemical: _____

4. A wave of contraction that moves food through the esophagus is called _____.

5. Name the folds found in the interior of an empty stomach. _____

6. List the three parts of the small intestine:

7. The two major functions of the small intestine are the _____ and _____ of nutrients.



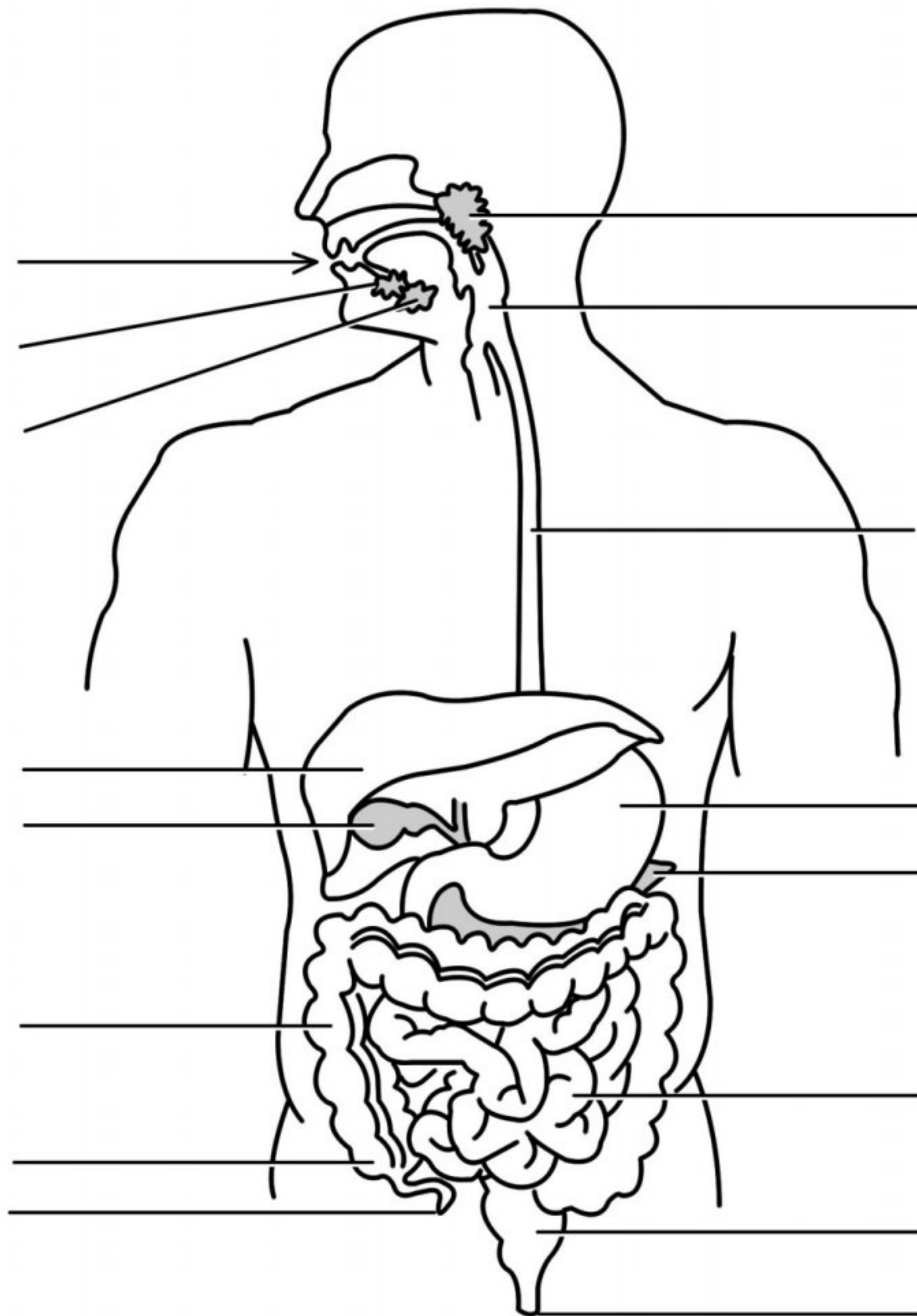
Name: _____

Date: _____

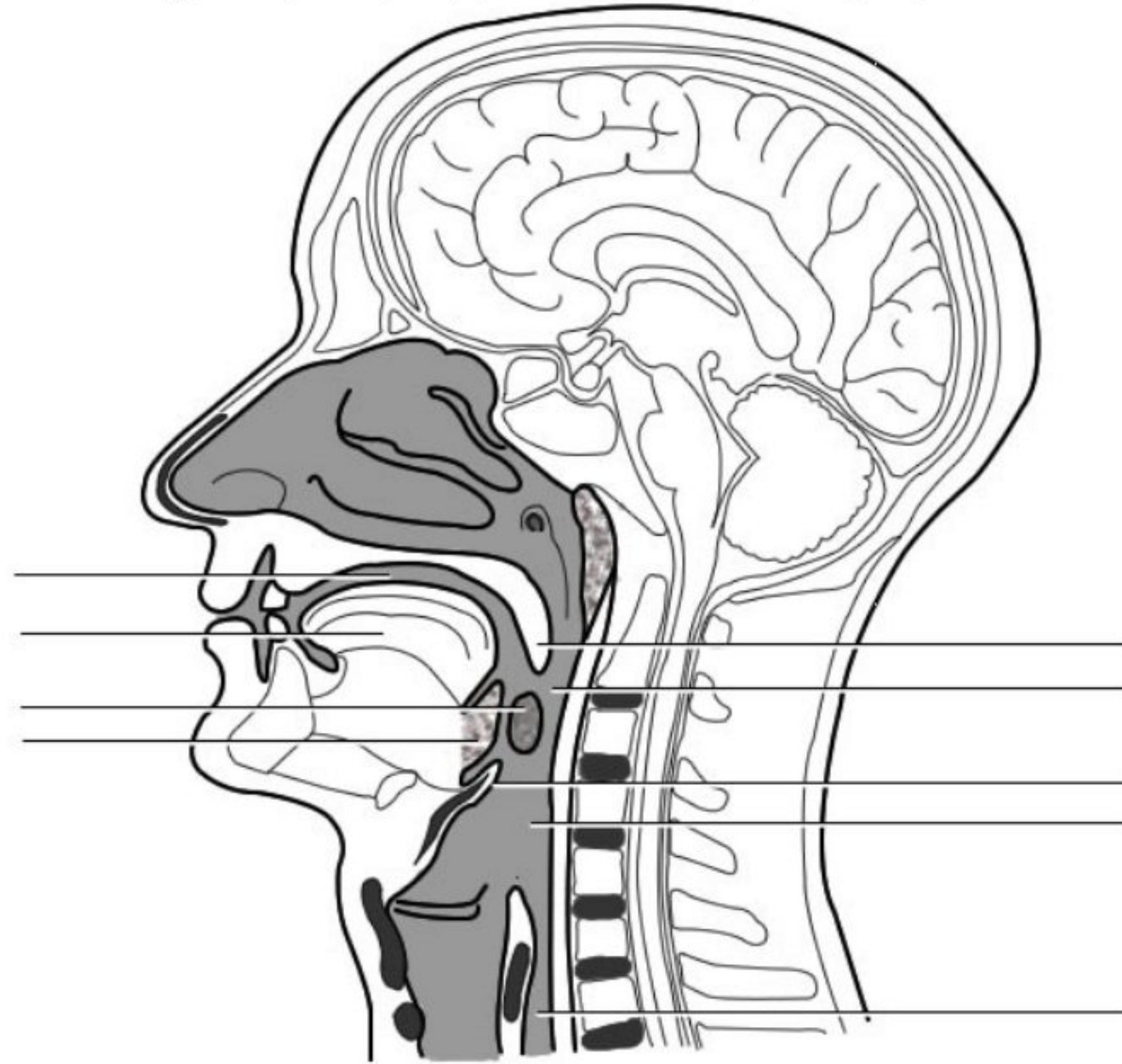
13. *The Digestive System*

A. Anatomy of the digestive tract

1. Label the parts of the digestive system: **anus, appendix, cecum, colon, esophagus, gall bladder, liver, mouth, pancreas, parotid gland, pharynx, rectum, small intestine, stomach, sublingual salivary gland, submandibular salivary gland**



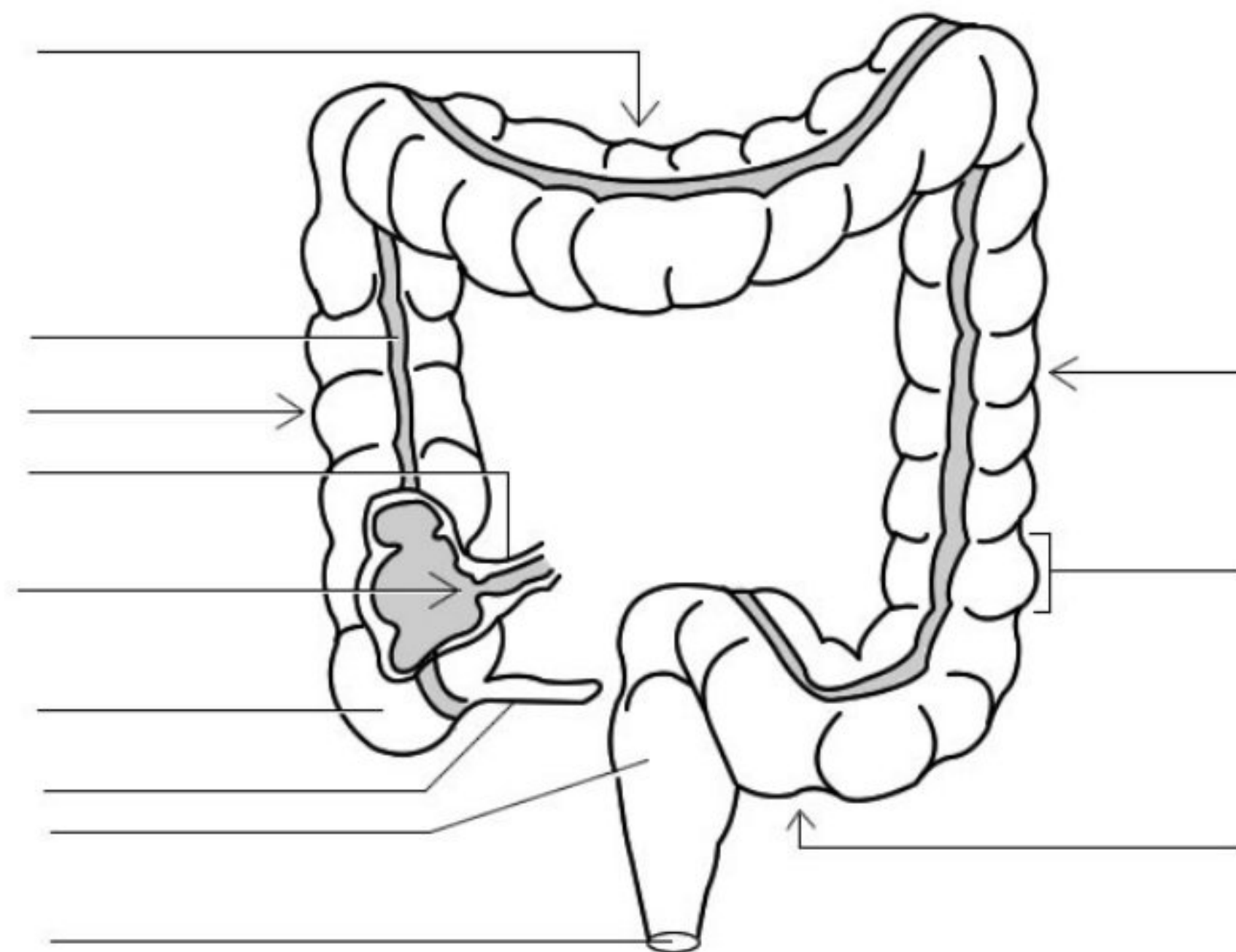
2. Label the midsagittal section of the head and neck: **epiglottis, esophagus, laryngopharynx, lingual tonsil, oral cavity, oropharynx, palatine tonsil, tongue, uvula**



3. Name the type of epithelium lining the oral cavity, oropharynx and laryngopharynx.

What role does it play in these spaces? _____

4. Label the parts of the large intestine: **anus, appendix, ascending colon, cecum, descending colon, haustra, ileocecal sphincter, ileum, rectum, sigmoid colon, teniae coli, transverse colon**



5. Give a function of each of the following parts of the digestive tract.

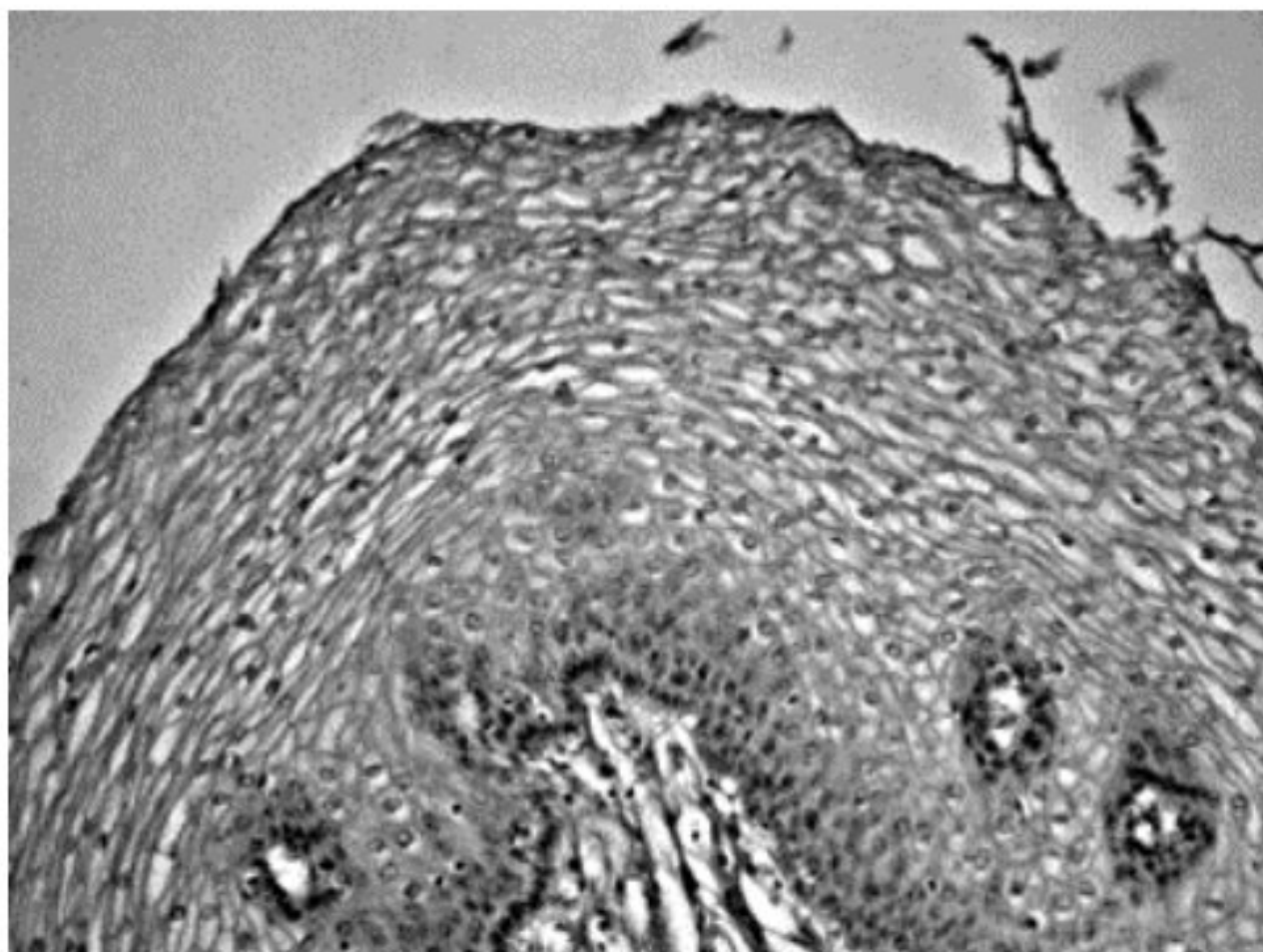
Part	Functions
Teeth	
Tongue	
Salivary glands	
Esophagus	
Stomach	
Small intestine	
Large intestine	
Uvula	
Epiglottis	

6. Name the sphincters that control movement between the parts of the digestive tract listed below.

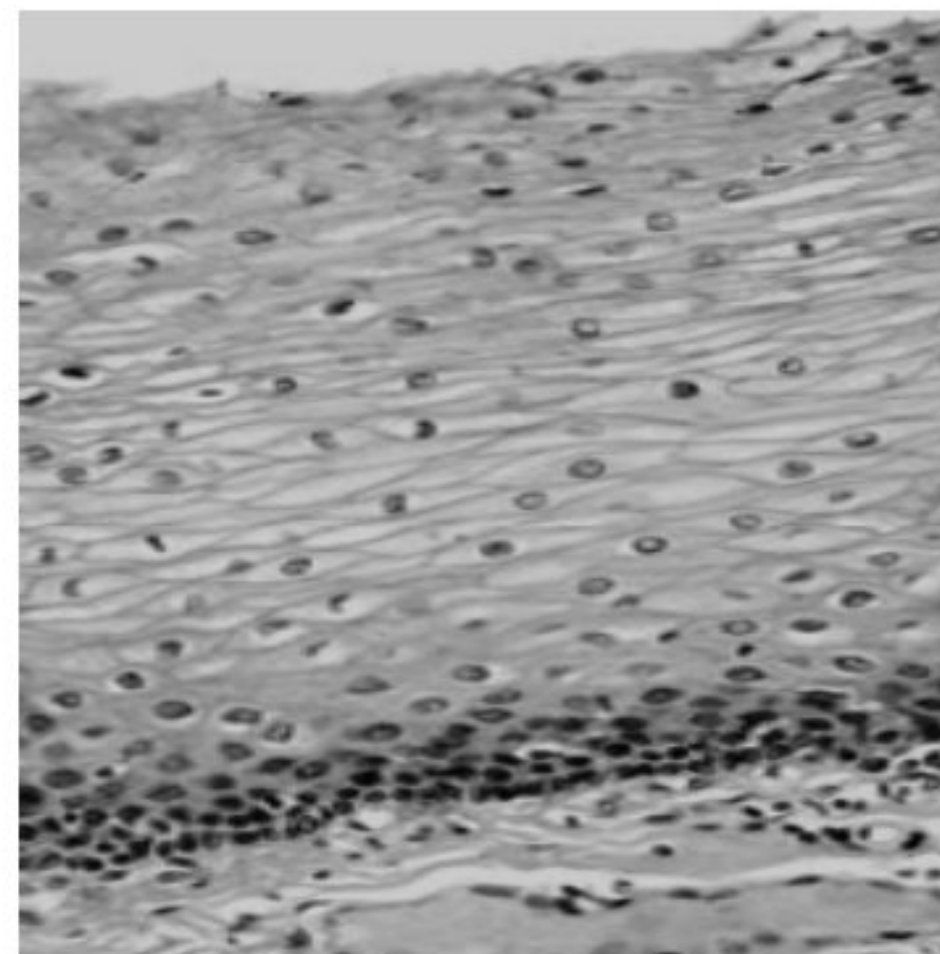
Name of the sphincter	Location the sphincter
	Between the laryngopharynx and the esophagus
	Between the esophagus and the stomach
	Between the stomach and the duodenum
	Between the ileum of the small intestine and the cecum
	Between the anus and the exterior: smooth muscle
	Between the anus and the exterior: pelvic diaphragm (skeletal)

B. Histology of the digestive tract

1. Observe the mucosa of the esophagus.



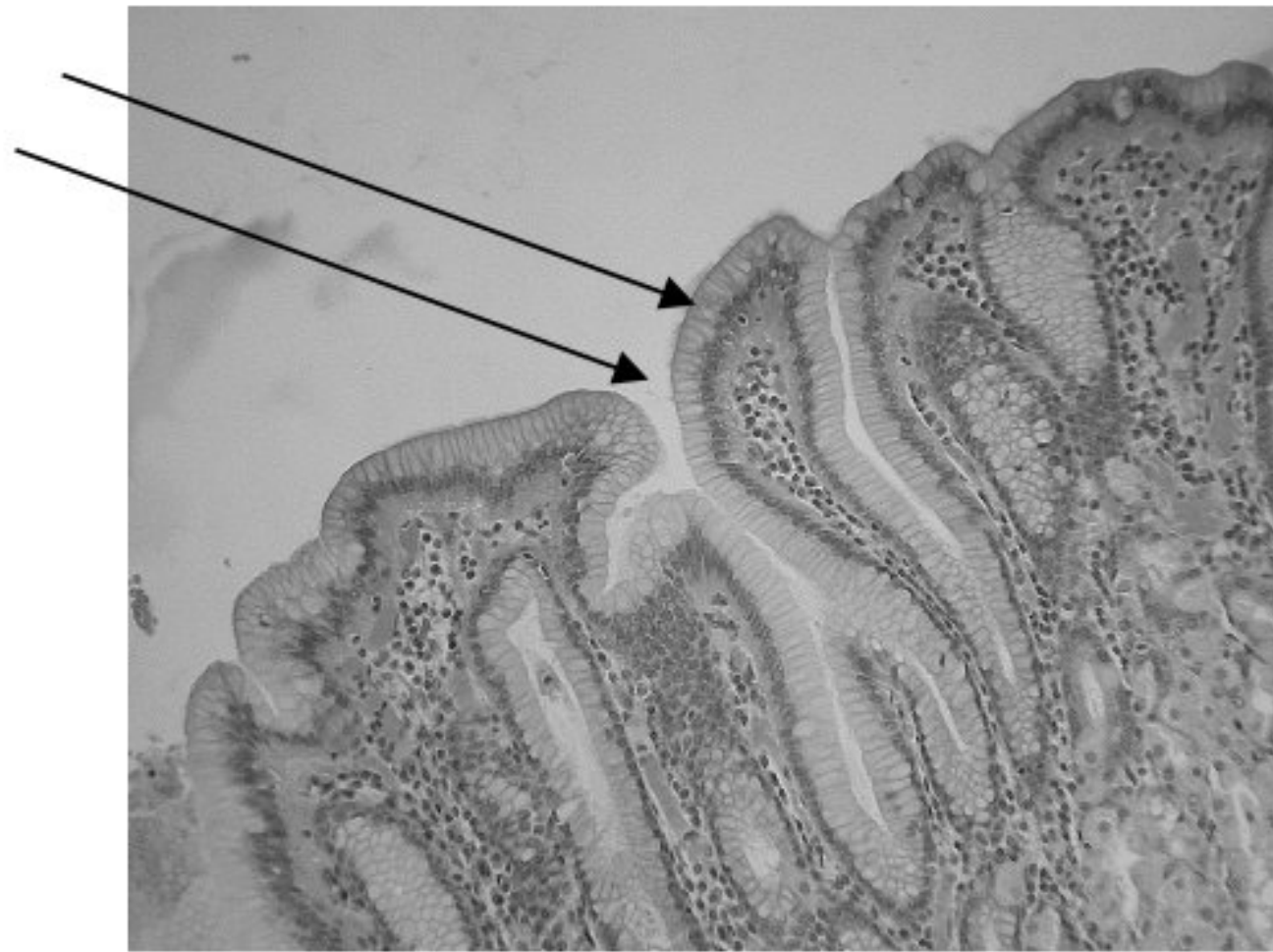
100X



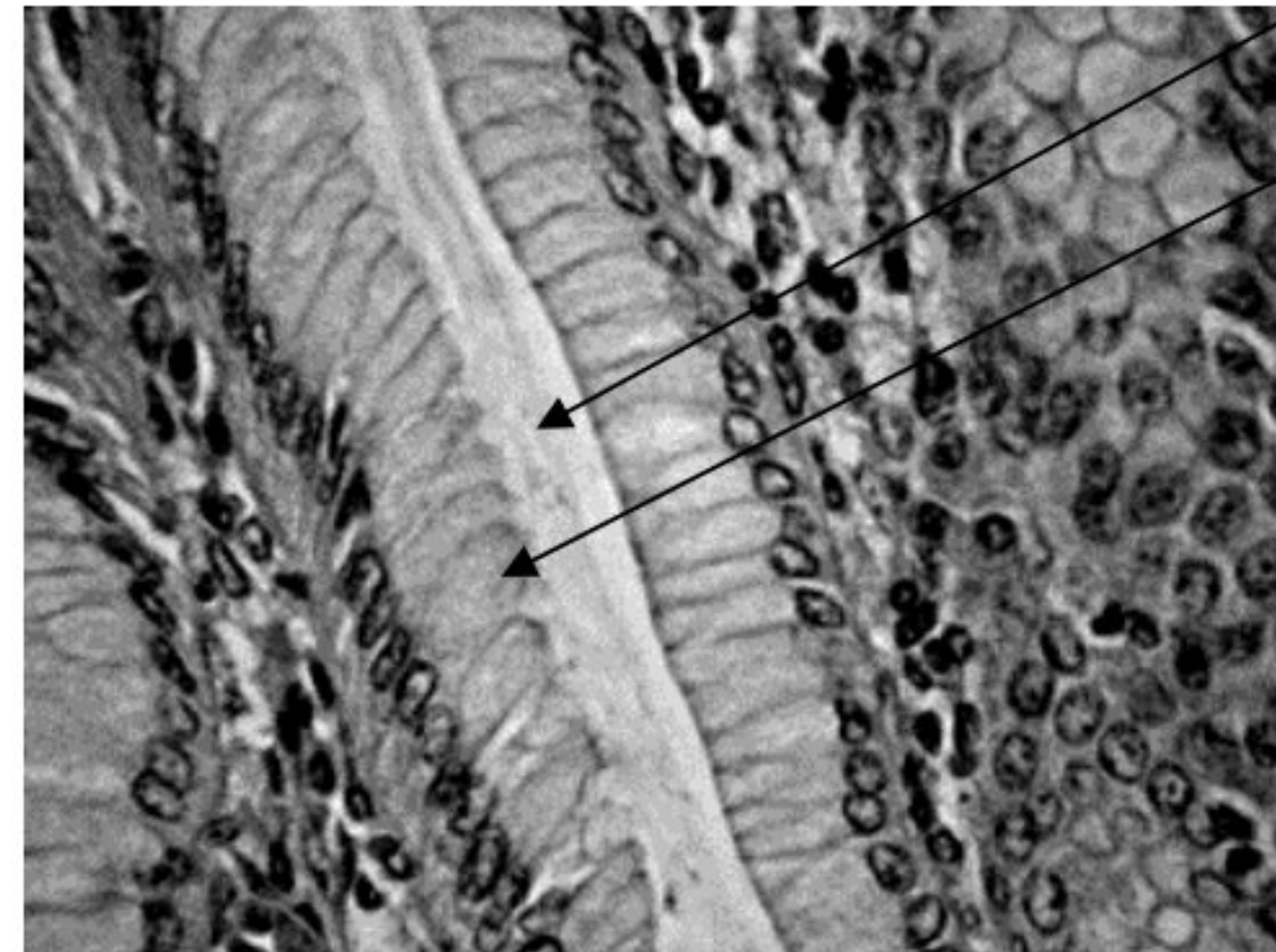
400X

What type of epithelium lines the inner surface of esophagus and why do you expect to find this type of epithelium in this organ?

2. For the mucosa of the stomach, label: **gastric pit**, **epithelium**



100X



400X

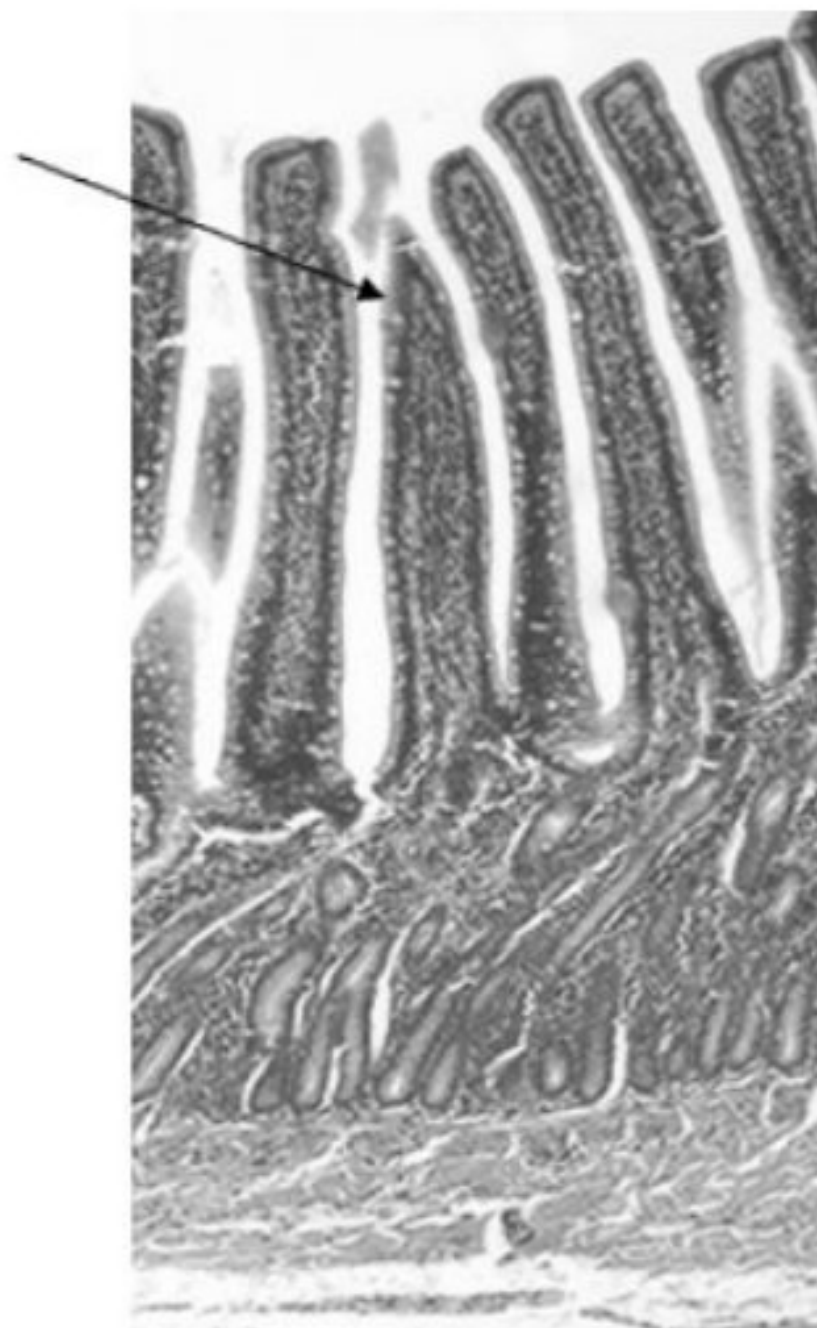
What type of epithelium lines the stomach? _____

What is secreted through the gastric pits? _____

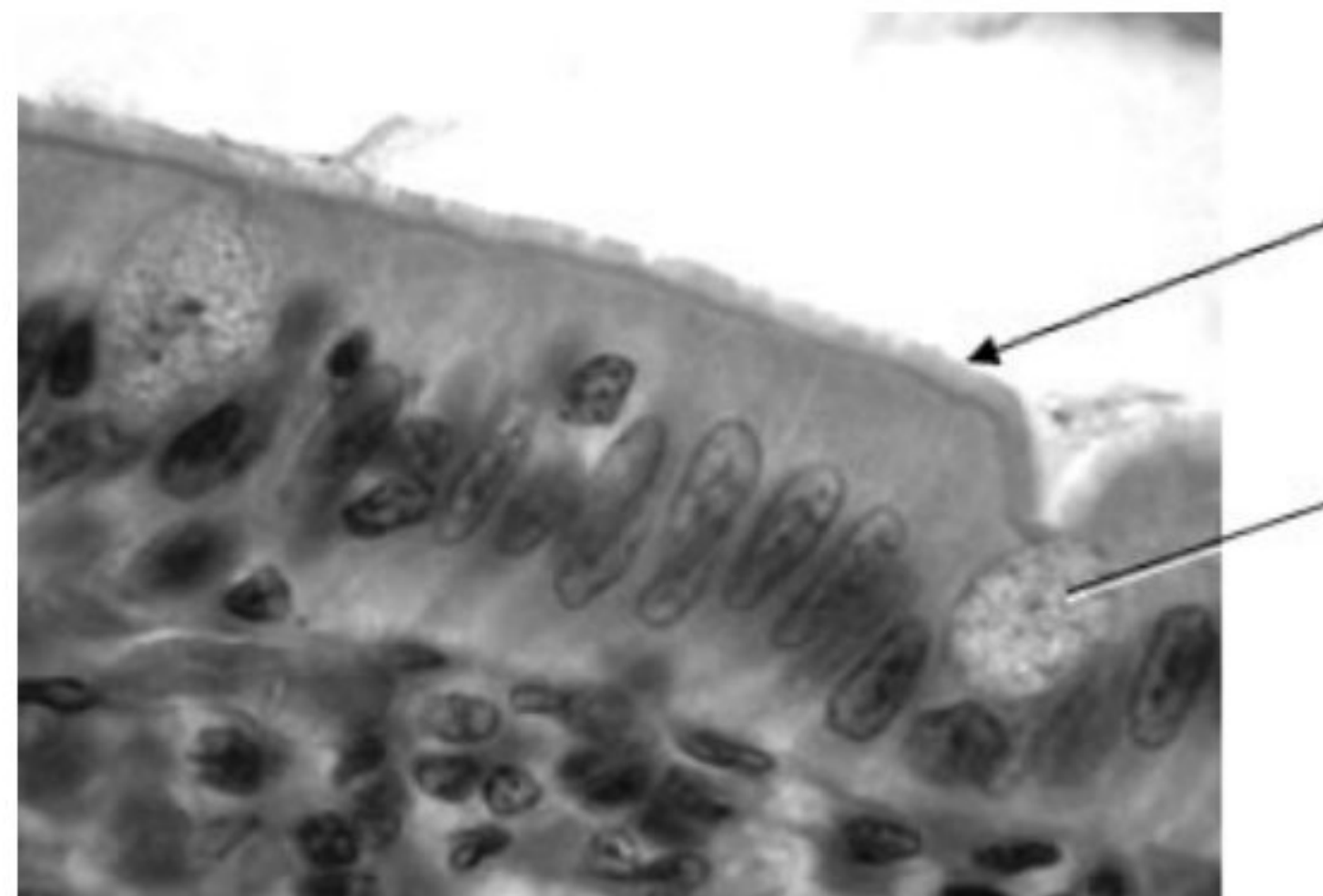
What does this secretion contain? _____

How many layers of muscles does the stomach wall have? _____

3. For the mucosa of the small intestine, label: **villi**, **goblet cell**, **microvilli**



100X



1000X

What type of epithelium lines the small intestine? _____

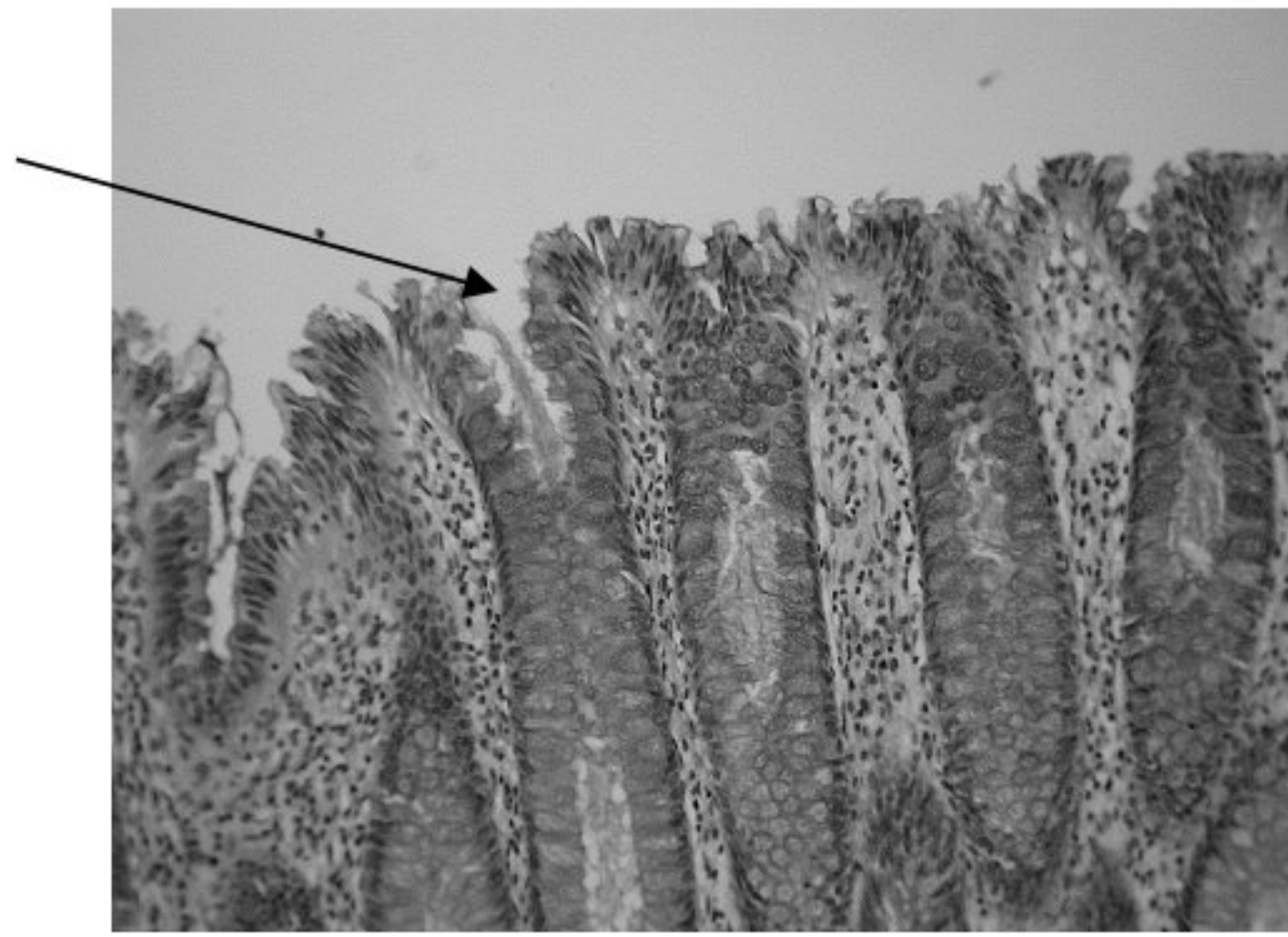
Give the roles of the following structures of the small intestine.

a. Villi: _____

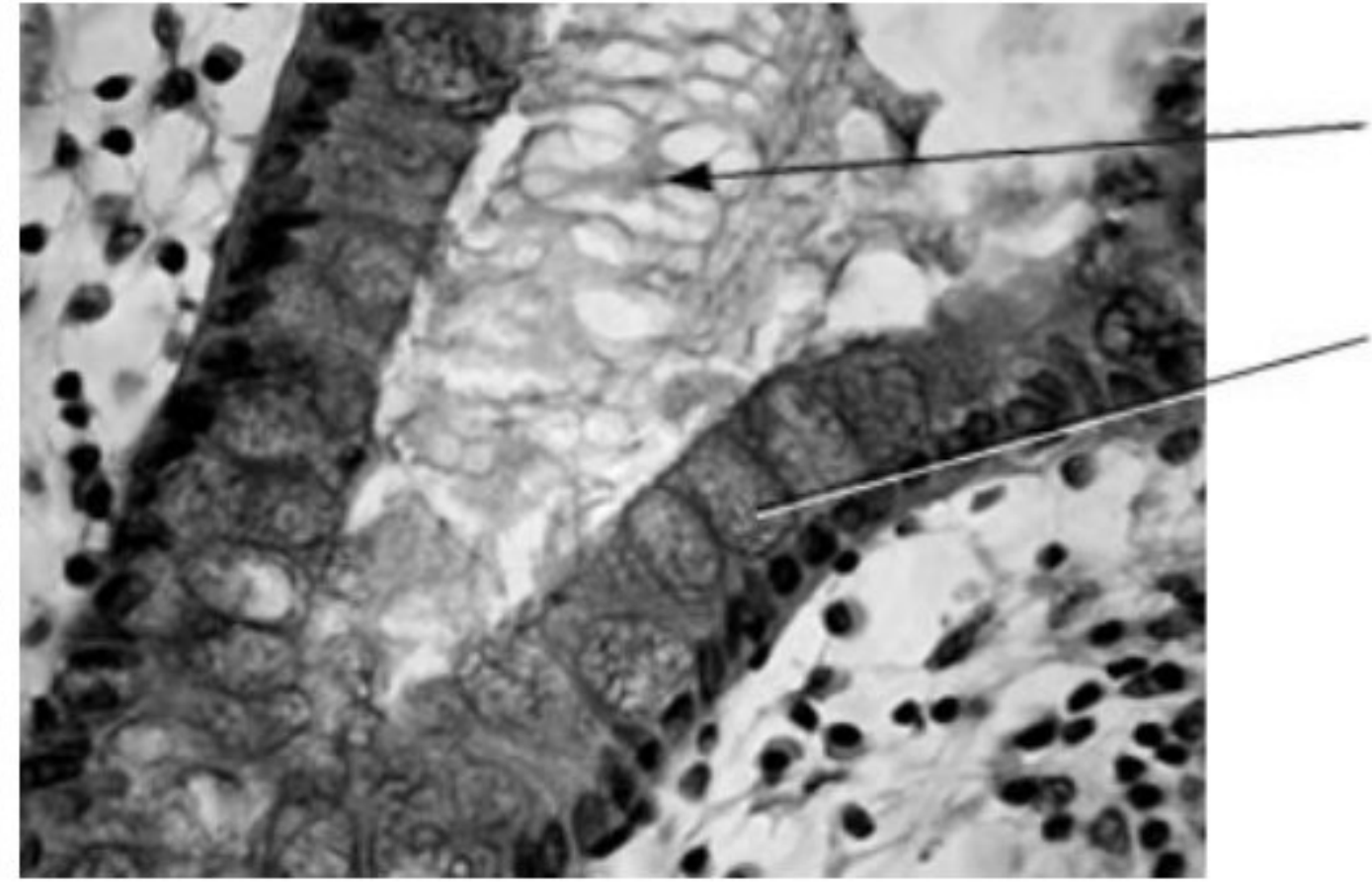
b. Microvilli: _____

To what does the term “brush border” refer and what is its role in digestion?

4. For the photomicrographs of the large intestine, label: **crypt**, **mucus**, **goblet cells**



100X



400X

What type of epithelium lines large intestine? _____

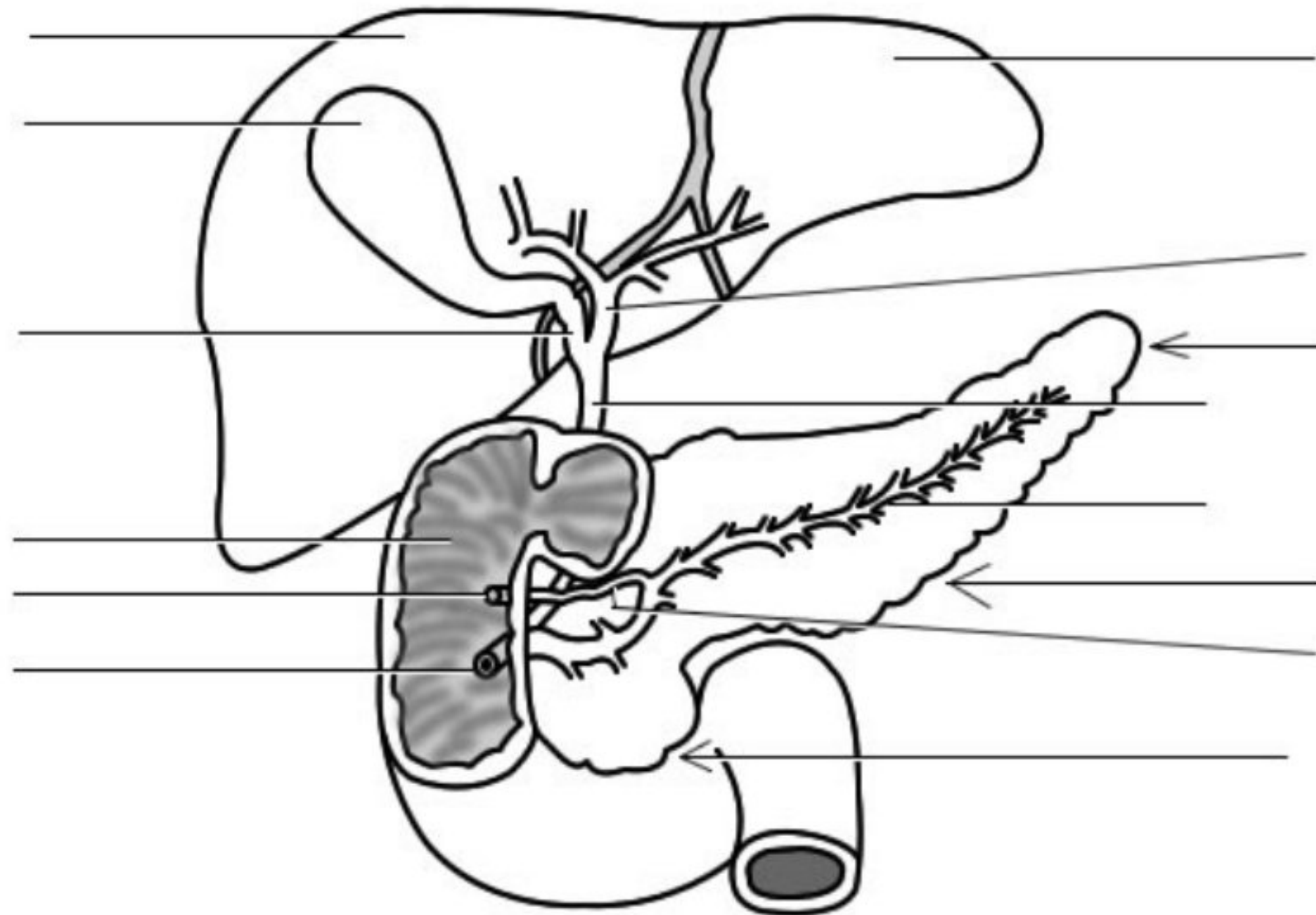
Why are there so many goblet cells in the epithelium? _____

C. Accessory Organs

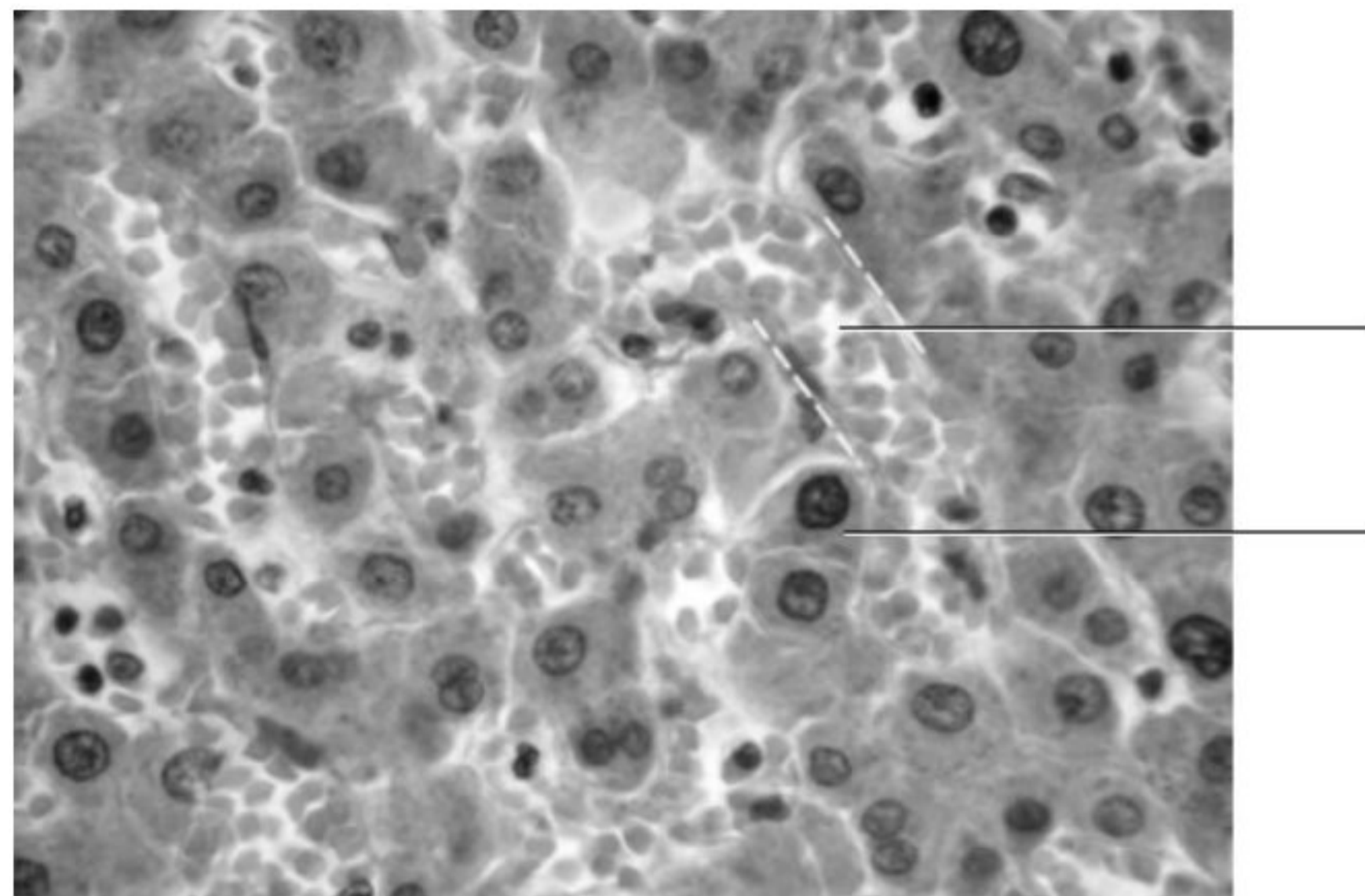
1. Give a function of each of the following accessory organs associated with the digestive system:

Accessory Organs	Functions
Liver	
Gall bladder	
Pancreas	

2. Label the figure of the biliary and pancreatic system: **body of pancreas, common bile duct, cystic duct, duodenum, gall bladder, head of pancreas, major duodenal papilla, left lobe of the liver, minor duodenal papilla, pancreatic duct, right lobe of liver, tail of pancreas, accessory duct**



3. Label the following photomicrograph of the liver: **hepatocytes, sinusoids**



400X

4. List three components of bile and give their significance.

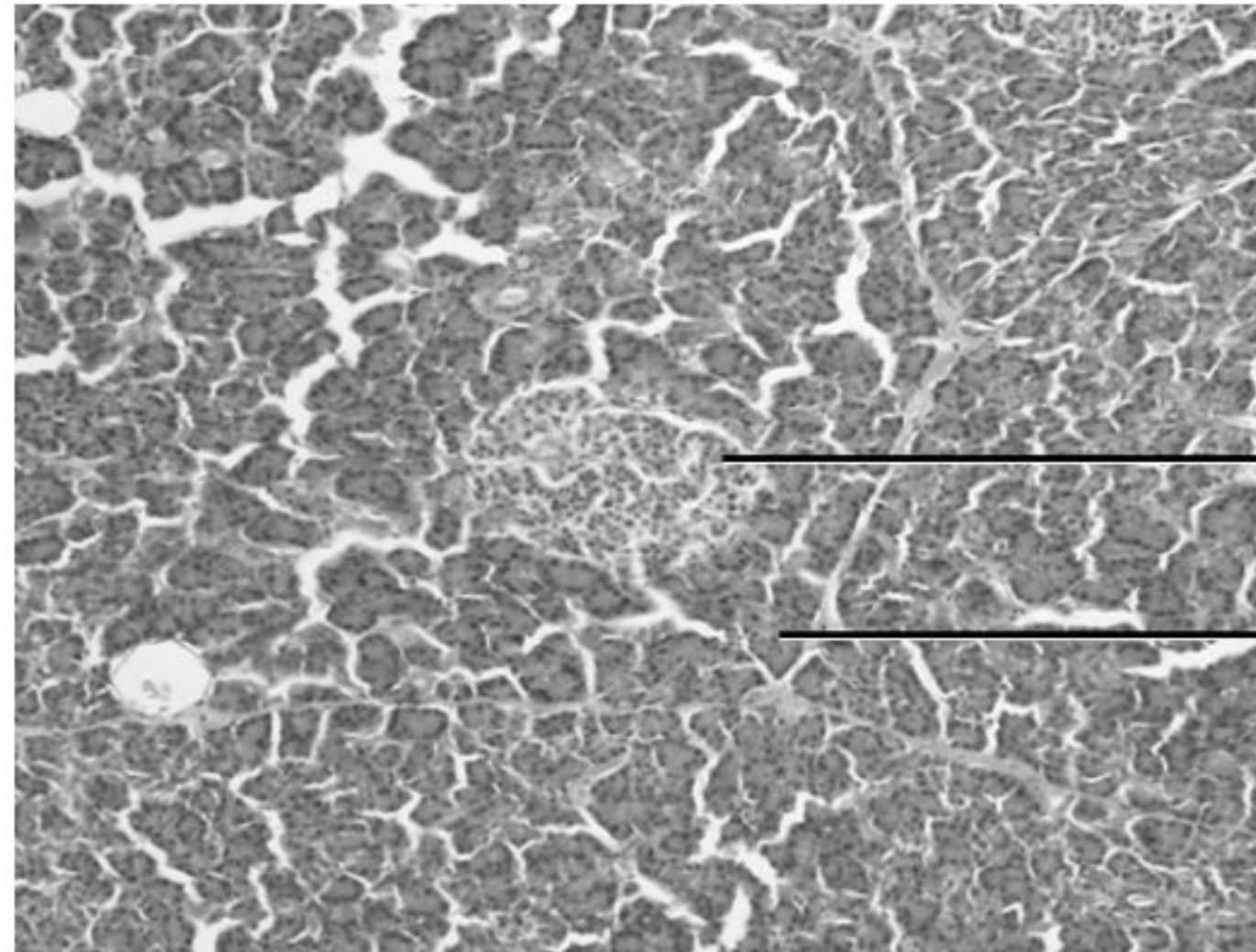
a. _____

b. _____

c. _____

5. Describe the functional relationship between the liver and the gall bladder.

6. Label the following photomicrograph of the pancreas: **acini cells, pancreatic islets**



100X

7. Fill in the table below concerning the photomicrograph of the pancreas.

Tissues of Pancreas	Classify (Endocrine or Exocrine)	Specific secretions
Acini cells		
Pancreatic islets (Islets of Langerhans)		

MAKE THE CONNECTION

1. If the salivary glands stop secreting saliva, list four functions that will be affected.

2. About 30 minutes to 2 hours after eating or drinking foods containing dairy products, a person develops symptoms that include nausea, cramps, bloating, gas, and diarrhea.

What is this person suffering from? _____

What is causing these symptoms? _____

3. About 30 minutes to an hour after a meal, a person feels pain in the upper right side of the abdomen. The pain comes and goes in waves as strong muscular contractions. This occurs especially after eating fatty foods. What do you think is causing this and why is it connected to fatty foods?

4. A 55-year old male patient with a history of hepatitis presents to his physician with markedly swollen ankles and abdomen. In addition, bruising is seen on the backs of his hands. As part of his exam, the doctor identifies that bleeding time is prolonged.

A. Why is a history of liver disease significant when looking at pathologies of the blood?

B. How does the liver influence the movement of fluid into the abdomen and the ankles?

C. How does the liver influence the bleeding time? _____

D. How does the liver affect the bruising? _____

5. What is the role of the following secretions of the digestive tract and its accessory organs?

Secretions	Role in Digestion
Alkaline buffers in pancreatic juice	
Hydrochloric acid secreted by the stomach	
Bile salts	
Mucus secreted by the stomach	
Mucus secreted by the large intestine	

Pre-Lab

Name: _____

14. *The Male Reproductive System*

1. In which organ of the male reproductive system does spermatogenesis take place?

2. Where in the male reproductive system are the sperm stored and mature?

3. Name two hormones produced by the testes and the cell types that produce these hormones.

a. _____

b. _____


4. The spermatic cord enters the abdominal cavity through the _____.

What constitutes the spermatic cord? _____

5. The penis is a passageway for _____ and _____.

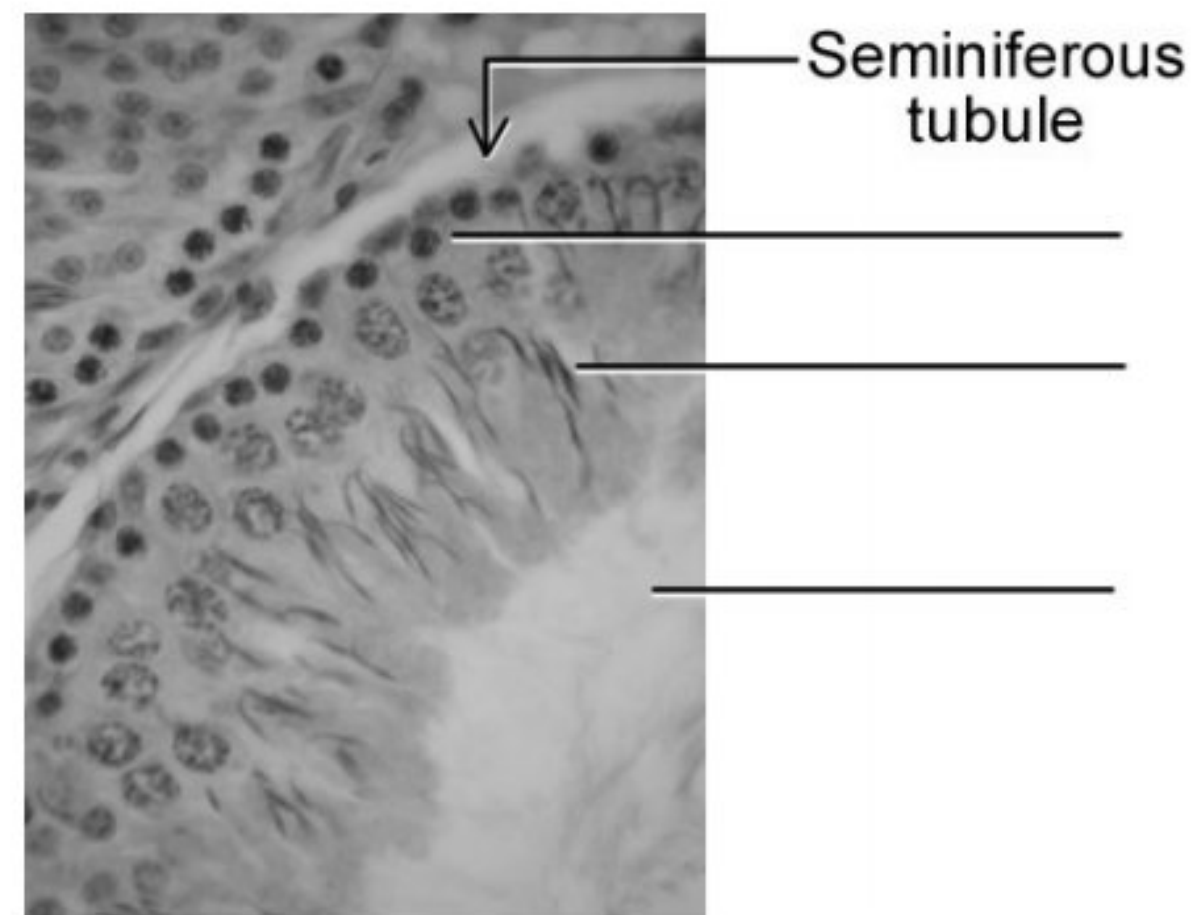
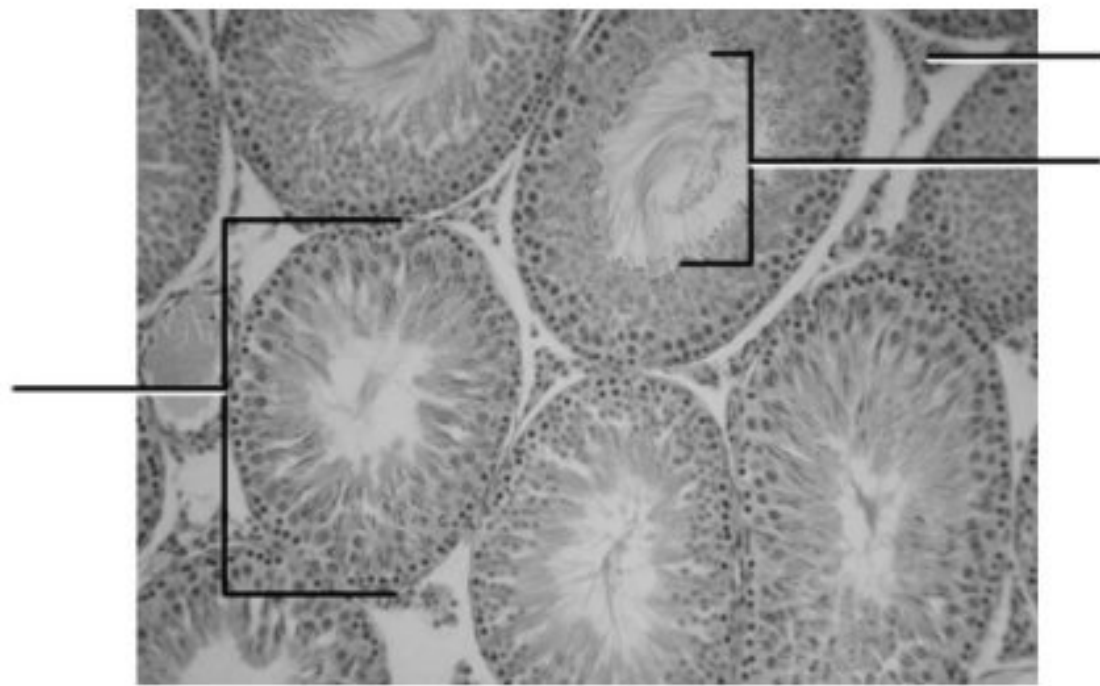
6. Name the three accessory glands that add fluid to the ejaculate.

3. Fill in the blanks for the correct sequence of tubes through which sperm travel: **ejaculatory duct, epididymis, external urethral orifice, membranous urethra, prostatic urethra, seminiferous tubules, spongy urethra, vas deferens**

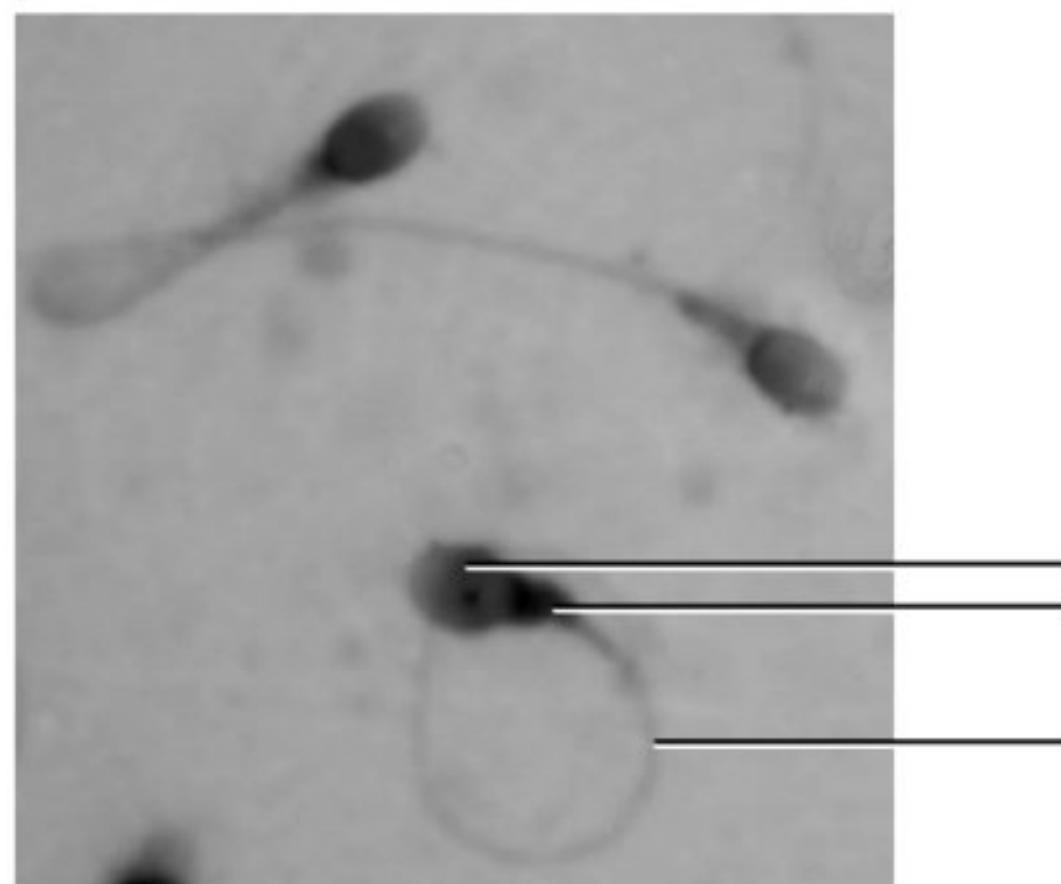


B. Histology of the male reproductive system

1. Label the parts of the testis cross section: **interstitial cells, lumen, seminiferous tubule, spermatagonia, and spermatids**



2. Label the parts of the sperm smear: **head, midpiece, tail.**



3. Complete the following table for the functions of the parts of a sperm.

Part of Sperm	Function/s
Acrosome in the head	
Nucleus in the head	
Midpiece	
Tail	

4. List the functions of the following testicular cells:

Cells	Functions
Sustentacular cells (Sertoli cells)	
Interstitial cells	
Spermatogonia	

MAKE THE CONNECTION

1. The pediatrician, while checking a male newborn, found that the scrotal sacs were empty. Explain the situation discussing the consequences on spermatogenesis and the treatment of this condition.

2. After a vasectomy:

a. What does the ejaculate contain? _____

b. Do the testes still produce testosterone? _____

3. What is the effect of an enlarged prostate on the reproductive and urinary systems?

4. Why would an athlete take testosterone? What would we expect to see in a woman taking testosterone?

Pre-Lab

Name: _____

15. *The Female Reproductive System & Development*

1. Two functions of the ovaries are:
 - a. _____
 - b. _____
2. The sacs in the ovary where the female gamete develops are called _____.
3. In addition to making the gametes, these sacs also secrete _____.
4. When a primary oocyte undergoes meiosis, it forms four cells.
How many cells develop into functional gametes? _____
What happen to the other cells? _____
5. When does the development of female gametes begin? _____
When is it completed? _____
6. Oogenesis is the formation of _____ cell.
It takes place in the _____.
7. Define the following terms:
 - a. Cleavage divisions: _____
 - b. Morula: _____
 - c. Blastocyst: _____



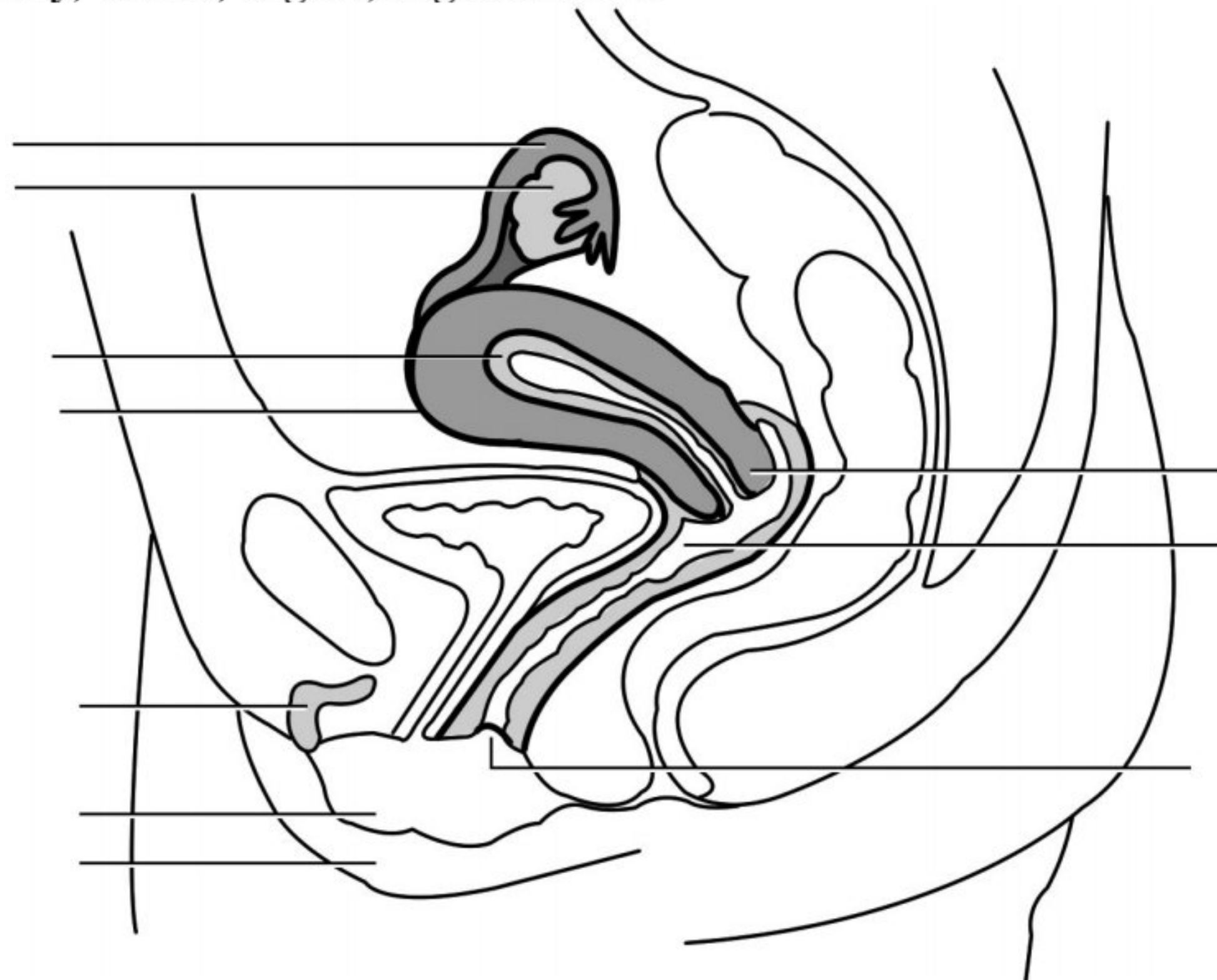
Name: _____

Date: _____

15. *The Female Reproductive System & Development*

A. **Anatomy of the female reproductive system**

1. Label the drawing of the female reproductive system and structures around it: **cervix, clitoris, endometrium of the uterus wall, fallopian (uterine) tube, labia minora, labia majora, ovary, uterus, vaginal orifice**



2. Give the functions of the parts of the female reproductive system.

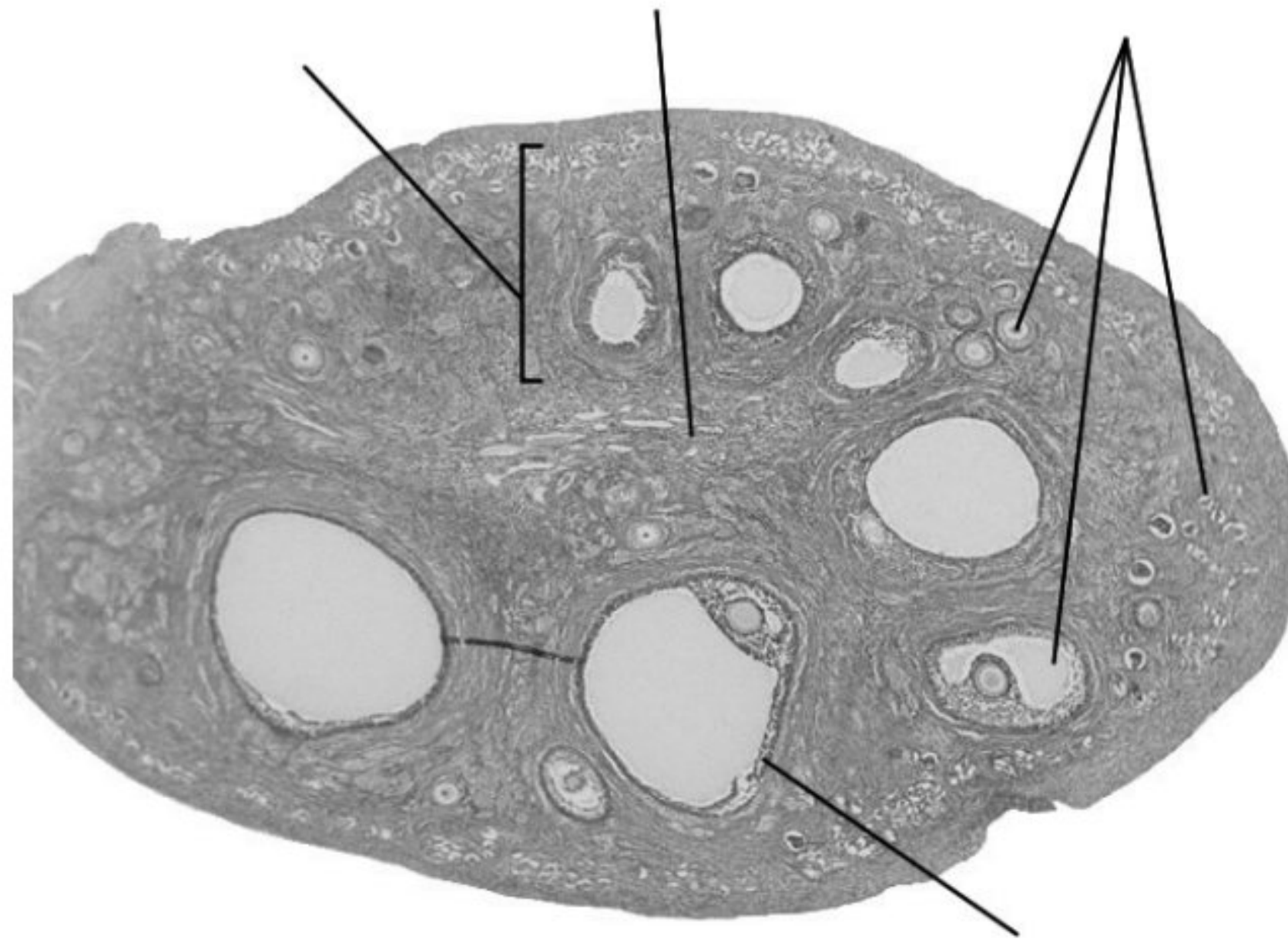
Part	Function/s
Ovary	
Ovarian ligament	
Infundibulum	
Oviduct	
Endometrium	
Myometrium	
Cervix	

3. Complete the following table for the functions of the hormones produced by the female reproductive system.

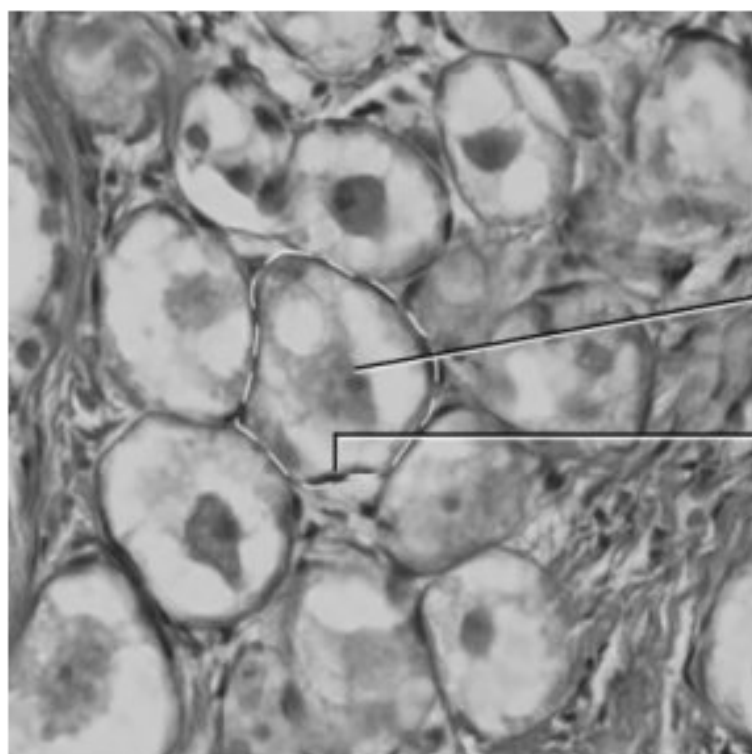
Hormone	Function/s
Estrogen	
Progesterone	
Inhibin	
Relaxin	

B. Histology of the female reproductive system

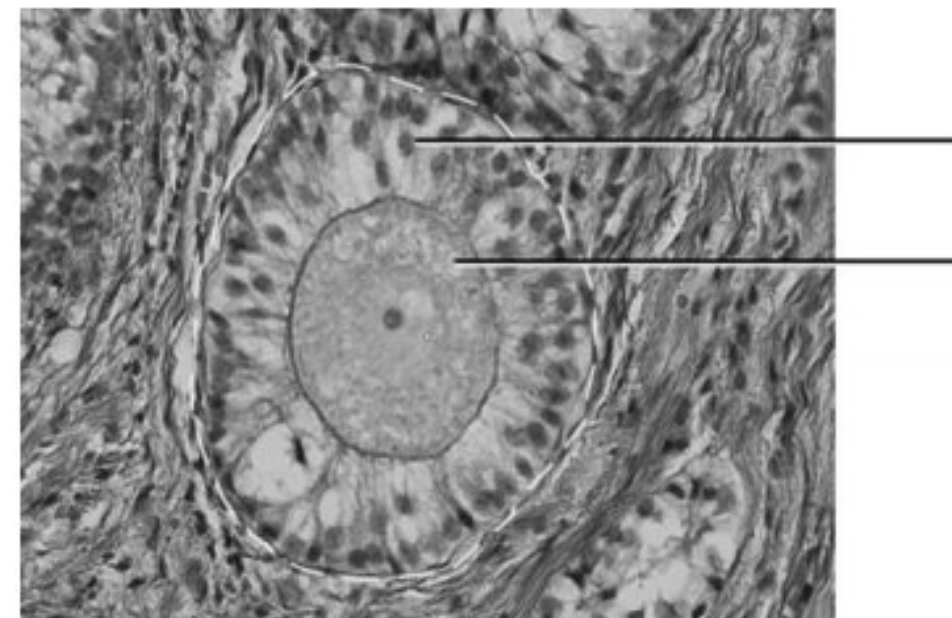
1. Label the parts of the ovary: **Graafian follicle, developing follicles, cortex, medulla**



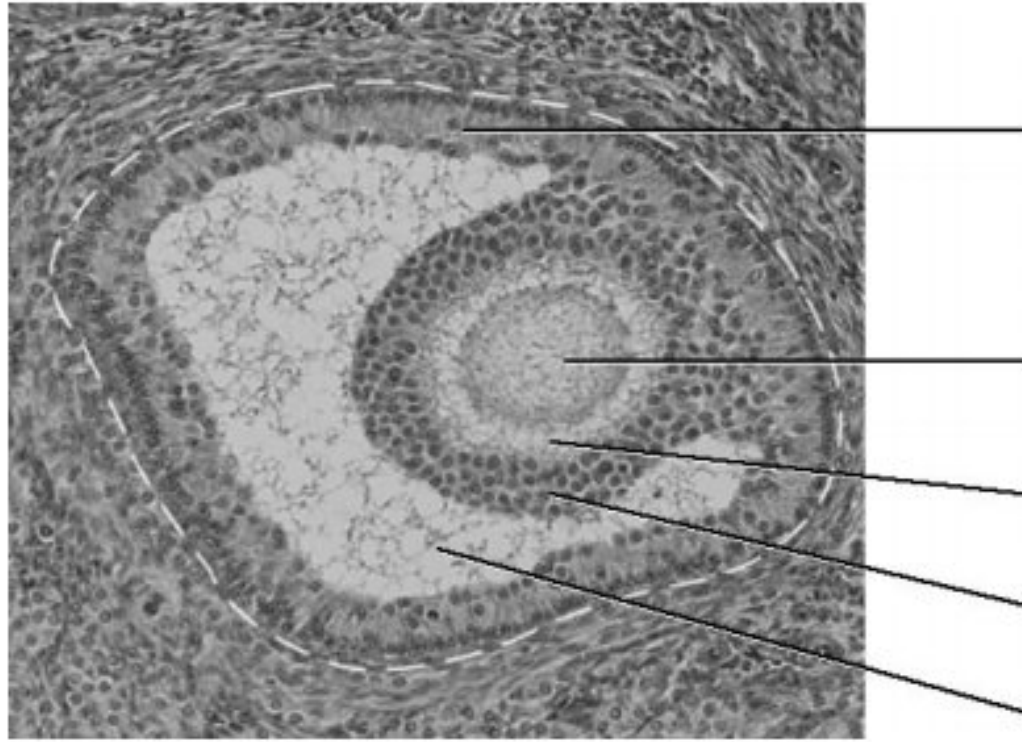
2. Label all the parts of the developing follicles.



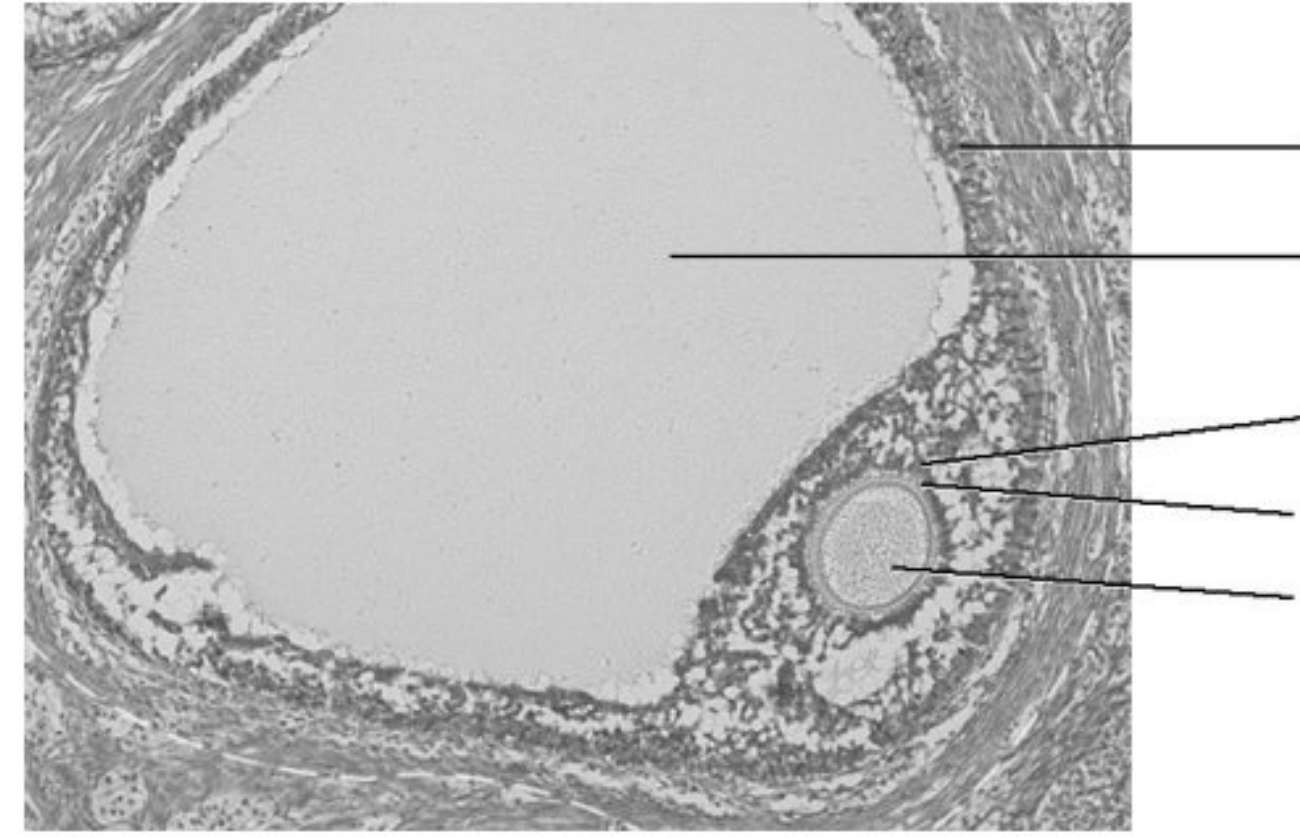
Primordial follicles: label **primary oocyte, follicular cell**



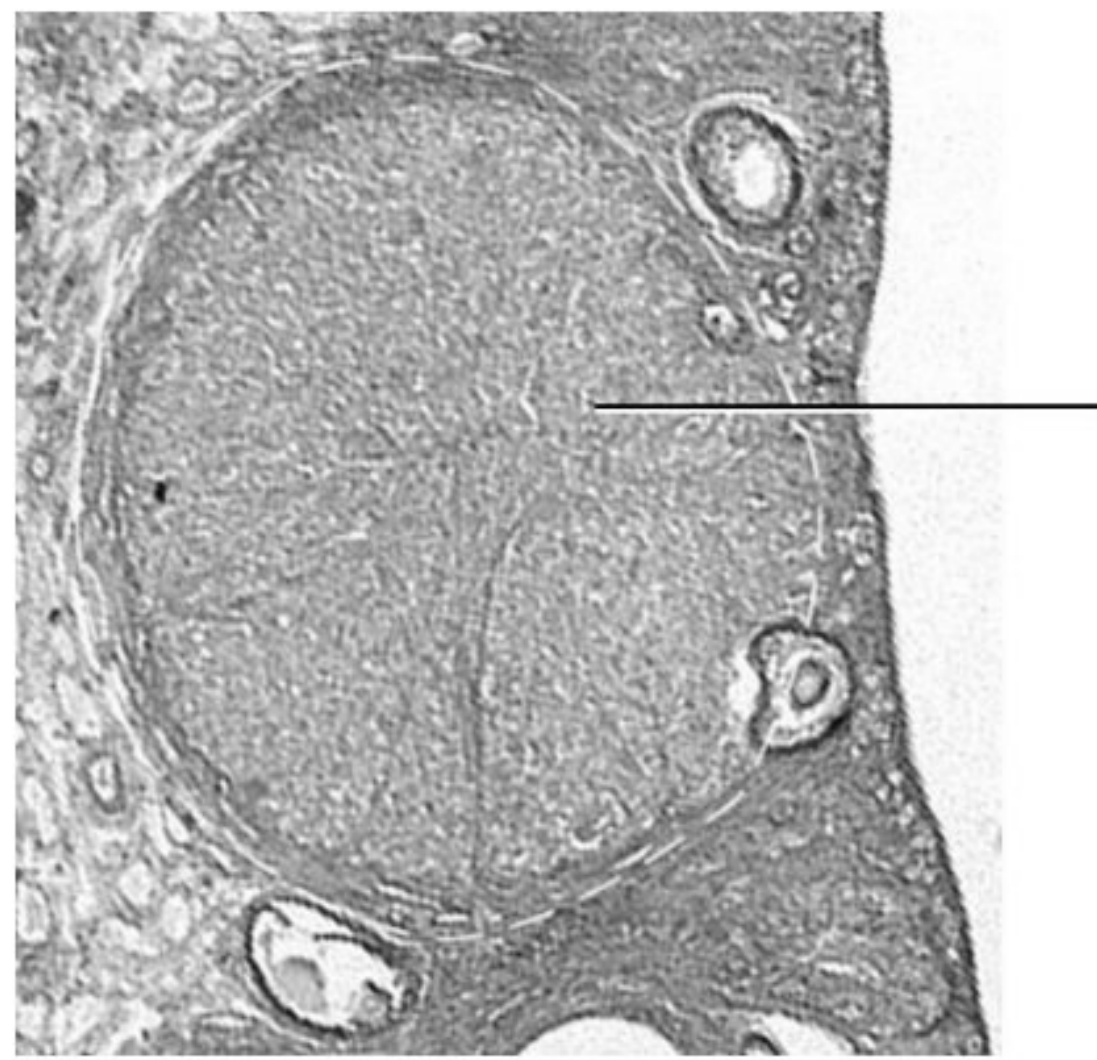
Primary follicle: label **primary oocyte, follicular cells**



Secondary follicle: label **primary oocyte, antrum, granulosa cells**



Graafian (mature) follicle: label **secondary oocyte, zona pellucida, corona radiata, antrum, granulosa cells**



Corpus luteum: label **granulosa cells**

3. Complete the following table with the number of autosomes and the types of sex chromosomes found at different stages of oocyte and spermatocyte development.

Stage in Female	# of autosomes and types of sex chromosomes	Stage in Male	# of autosomes and types of sex chromosomes
Primary oocyte		Primary spermatocyte	
Secondary oocyte		Secondary spermatocyte	
Ovum		Spermatozoan	

4. Name the hormone responsible for the following events:

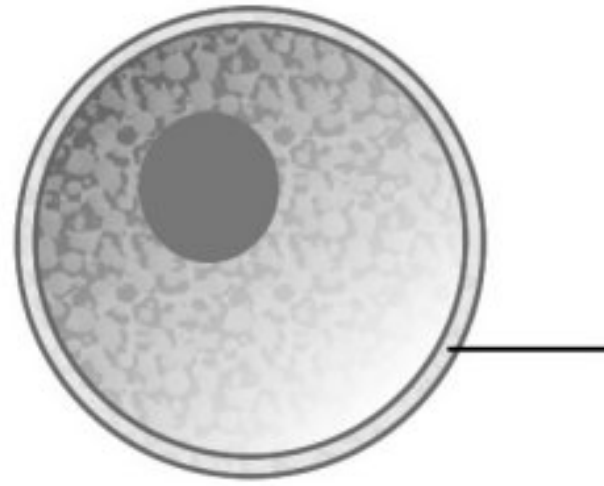
Stimulation of follicular development: _____

Ovulation: _____

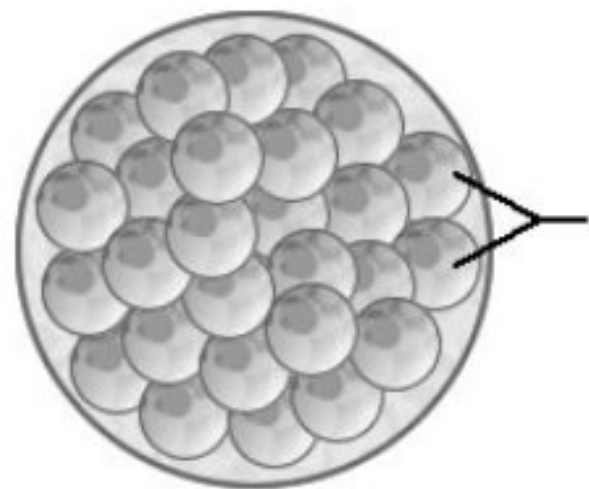
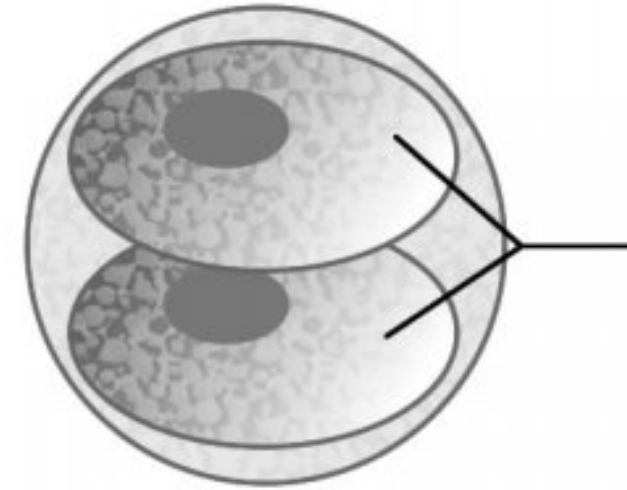
- At the time of ovulation, the female gamete is at _____ stage.
- List the hormone(s) produced by corpus luteum. _____

C. Development

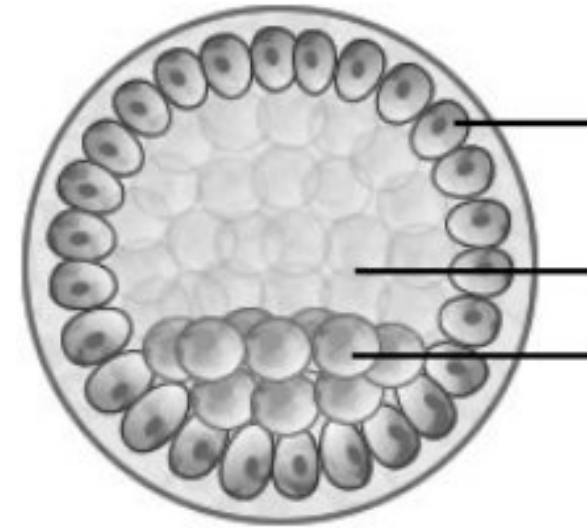
- Label the following embryo development stages and cells: **zygote, blastocoel, embryoblasts, blastomeres, morula, blastocyst, zona pellucida, trophoblasts**



Stage: _____



Stage: _____



Stage: _____

- How does the overall size of the early embryo compare with the size of the zygote?
Explain. _____
- At which stage of development does the embryo implant in the uterus? _____
- In which layer of the uterus does the embryo implant? _____

MAKE THE CONNECTION

- During breast-feeding, mothers often experience contractions of the uterus similar to those during labor. Explain this situation and its potential benefits to the mother.

- Name the two types of twins. _____, _____
Discuss how you can have twins that have the same or different genetic make-up?

